

LETTER TO THE EDITOR

Visually-sensitive networks in essential tremor: evidence from structural and functional imaging

Constantin Tuleasca,^{1,2,3,4} Jean Régis,⁵ Elena Najdenovska,² Tatiana Witjas,⁶ Nadine Girard,⁷ Jean-Philippe Thiran,^{3,4,8} Meritxell Bach Cuadra,^{2,3} Marc Levivier^{1,4} and Dimitri Van De Ville^{9,10}

- 1 Centre Hospitalier Universitaire Vaudois (CHUV), Neurosurgery Service and Gamma Knife Center, Lausanne, Switzerland
- 2 Medical Image Analysis Laboratory (MIAL) and Department of Radiology-Center of Biomedical Imaging (CIBM), Centre Hospitalier Universitaire Vaudois, Lausanne, Switzerland
- 3 Signal Processing Laboratory (LTS 5), Ecole Polytechnique Fédérale de Lausanne (EPFL), Switzerland
- 4 University of Lausanne, Faculty of Biology and Medicine, Lausanne, Switzerland
- 5 Stereotactic and Functional Neurosurgery Service and Gamma Knife Unit, CHU Timone, Marseille, France
- 6 Neurology Department, CHU Timone, Marseille, France
- 7 AMU, CRMBM UMR CNRS 7339, Faculté de Médecine and APHM, Hopital Timone, Department of Diagnostic and Interventional Neuroradiology, Marseille, France
- 8 Centre Hospitalier Universitaire Vaudois, Department of Radiology, Lausanne, Switzerland
- 9 University of Geneva, Faculty of Medicine, Switzerland
- 10 Medical Image Processing Laboratory, Ecole Polytechnique Fédérale de Lausanne (EPFL), Switzerland

Correspondence to: Constantin Tuleasca, MD, MD-PHD candidate
Centre Hospitalier Universitaire Vaudois, Neurosurgery Service and Gamma Knife Center
Rue du Bugnon 44-46, BH-08, CH-1011, Lausanne, Switzerland
E-mail: constantin.tuleasca@gmail.com

Correspondence may also be addressed to: Dimitri Van De Ville
E-mail: dimitri.vandeville@epfl.ch

Sir,

Archer *et al.* (2018) provide new evidence of a wide-spread visually-sensitive functional network, including extrastriate areas V3 and V5, which relates to tremor severity in patients with essential tremor. They obtained right-hand force measurements during functional MRI of a grip-force task while they manipulated visual feedback. The authors conclude that the severity of tremor is exacerbated by increased visual feedback, suggesting that designers of new computing technologies should consider using lower visual feedback to reduce tremor in essential tremor. Furthermore, the network-level characterization of essential tremor would not solely be confined to the cerebello-thalamo-cortical pathway (Kelly and Strick, 2003). Likewise, in the light of this evidence, surgical targeting for drug-resistant tremor should be refined in the future, while the current two main sites are thalamic ventro-

intermediate nucleus (VIM) (Fox *et al.*, 1991; Benabid *et al.*, 1996; Witjas *et al.*, 2015; Elias *et al.*, 2016) and posterior subthalamic area (PSA) (Blomstedt *et al.*, 2010).

We have recently published two voxel-based morphometry (VBM) reports (Tuleasca *et al.*, 2017b, 2018b) and one resting-state functional MRI report (Tuleasca *et al.*, 2018a), in which we provide evidence of the implication of a wide-spread visually-sensitive structural and functional network in essential tremor, which is affected by thalamotomy. The clinical studied parameter was tremor score on right treated hand, from the standard Fahn-Tolosa-Marin tremor rating scale (Fahn *et al.*, 1988). Archer *et al.* (2018) cited one of our VBM studies (Tuleasca *et al.*, 2017b), in which we reported that grey matter density changes in a larger occipital cluster, including Brodmann area (BA) 19, V4, V5 and parahippocampal place area, relate to tremor arrest after VIM radiosurgery. However, this mention follows a

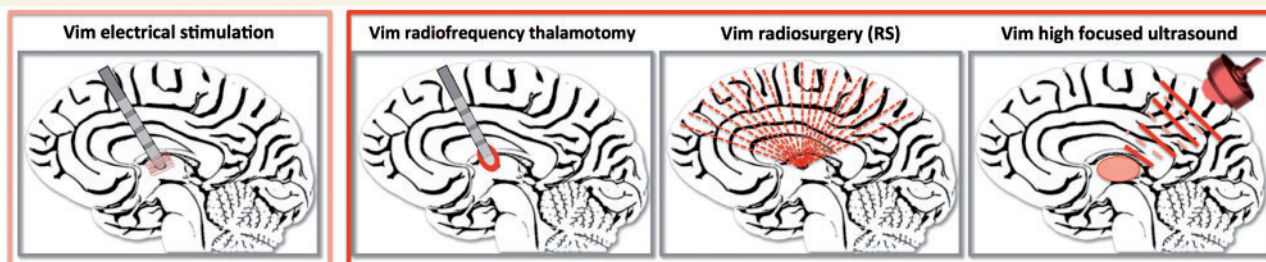


Figure 1 Artistic representation of the current surgical treatments for tremor targeting the VIM. Left to right: VIM electrical stimulation; VIM radiofrequency thalamotomy; VIM radiosurgery; VIM high focused ultrasound.

reference to Fytagoridis *et al.* (2012), which is a study on deep brain stimulation targeting the VIM, originally pioneered by Benabid *et al.* (1996) (Fig. 1). Therefore, it might suggest that the structural changes that we observed (Tuleasca *et al.*, 2017b), were also following thalamic electrical stimulation. Nevertheless, this is not the case, since the investigated cohort had benefited from unilateral left VIM radiosurgery (Witjas *et al.*, 2015), which mimics in part the effect of a stereotactic radiofrequency thalamotomy (Fig. 1) (Schuurman *et al.*, 2000), with an additional considered neuromodulatory effect (Regis *et al.*, 2010; Tuleasca *et al.*, 2017a). Radiosurgery of the VIM (Fig. 1) is one of the minimally invasive alternatives to open standard stereotactic procedures for tremor (Witjas *et al.*, 2015). Unlike radiosurgery, another possibility, modern high-focused ultrasound (HIFU, Fig. 1) (Elias *et al.*, 2016), produces a controlled thermocoagulation, with immediate clinical and radiological effect. In another VBM study (Tuleasca *et al.*, 2018b), we showed that pretherapeutic grey matter density in right extrastriate cortex BA 18 was predicting tremor score on right treated hand improvement 1 year after VIM radiosurgery, to account for the delayed and progressive clinical effect.

In addition, we have investigated essential tremor patients using resting-state MRI (Tuleasca *et al.*, 2018a), acquired before and 1 year after VIM radiosurgery. We used data-driven multivariate analysis (i.e. independent component analysis; Calhoun *et al.*, 2001; Beckmann *et al.*, 2005) to conduct whole-brain analysis without prior assumptions. Statistical investigation was implemented in SPM12 as an ANOVA flexible factorial model, on each separate component, by using individual subject-level maps, to take into account time point (pretherapeutic versus 1 year after VIM radiosurgery), clinical response ($\leq 50\%$ versus $> 50\%$ improvement of the tremor score on right treated hand), as well as the interactions between. Bonferroni correction was used to deal with number of models ($n = 20$). We then reported corrected P -values using conventional cluster-level family wise error (FWE) correction. For relevant interconnectivity values, there was no influence of age or disease duration ($P > 0.05$).

We found two networks, which presented statistically significant interconnectivity with visual clusters. One

network reflected the interaction between time (pre- and 1 year post-therapeutic) with clinical effect; this included bilateral motor network, frontal eye-fields and left cerebellum lobule VI [the former as in the report of Archer *et al.* (2018)], of which network interconnectivity strength with right visual BA 19 related to tremor arrest after VIM RS [FWE = 0.001, Fig. 2A, top, upper part, adapted from Tuleasca *et al.* (2018a)]. Both pretherapeutic interconnectivity (Fig. 2A, middle), as well as difference between 1 year and baseline, related to tremor score on right treated hand improvement after VIM radiosurgery. Furthermore, patients who alleviated less presented negative pretherapeutic interconnectivity (which increased to median positive values 1 year later), while those who alleviated more, had already positive pretherapeutic values (which decreased to a median of 0, 1 year later) (Fig. 2A, bottom). The second network reflected the time effect independently of the clinical one; this included reminiscent of the salience network, which showed altered interconnectivity with right fusiform gyrus and V5 (FWE = 0.000, Fig. 2B, top). For this former network, opposite results as compared with the previous one were observed. Overall interconnectivity values decreased from slightly positive to the opposite slightly negative values (Fig. 2B, middle). Furthermore, patients who alleviated less presented slightly positive pretherapeutic interconnectivity (which decreased to median of slightly negative symmetric, close to 0, 1 year later), while those who alleviated more, had pretherapeutic negative median values (close to 0, which slightly increased to a median of 0, 1 year later) (Fig. 2B, bottom). We concluded, based on the previous, that VIM radiosurgery seems to bring interconnectivity in the visual areas back to normal for all patients, but the ones who had this region more functionally integrated pretherapeutically had much larger benefit.

Our findings suggest further explanation of the result of Archer *et al.* (2018). In particular, our resting-state functional MRI report provides complementary evidence of a widespread visually-sensitive functional network in essential tremor. Moreover, it is a cerebello-visuo-motor network that is responsible for tremor arrest after VIM radiosurgery. This is explanatory for a more prominent pathophysiological role, rather than a simple, individual, adaptive trait. We suggested that interconnectivity between these networks have a prone role in sensory guidance of

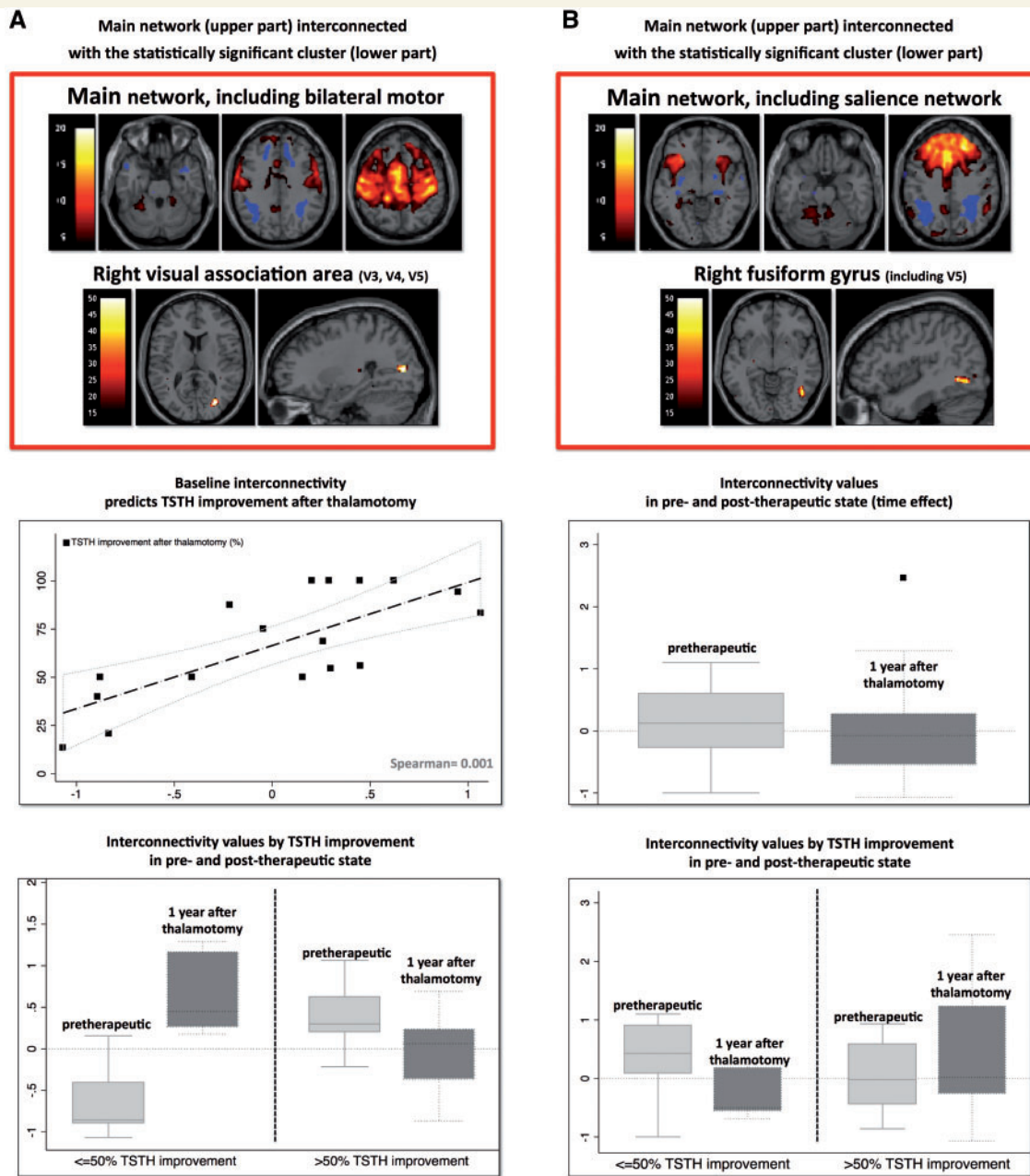


Figure 2 Main findings from our recent resting-state functional MRI study (adapted from Figures 2 and 8 in Tuleasca *et al.*, 2018a), before and 1 year after Vim radiosurgery. **(A)** Interaction between clinical effect and time. *Top*: Interconnectivity between the main network, including left cerebellum lobule VI, frontal eye fields and bilateral motor cortex with right visual association area (BA 19, including V3, V4 and V5). *Middle*: Pretherapeutic interconnectivity predicts tremor score on the treated hand improvement 1 year after Vim radiosurgery (Spearman rank correlation coefficient 0.001). *Bottom*: Boxplot illustration with regard to the group clinical effect ($\leq 50\%$ and $> 50\%$ improvement). **(B)** Main effect of time. *Top*: Interconnectivity between the main network, including remnant salience network with right fusiform gyrus (including V5). *Middle*: Boxplot illustration of overall interconnectivity values in pre- and post-therapeutic states. *Bottom*: Boxplot illustration with regard to the group clinical effect ($< 50\%$ and $> 50\%$ improvement).

movements of hands and fingers, and further in movement control (Tuleasca *et al.*, 2018a). We hypothesized that the input from the visual to the contralateral motor network could be calibrated by the corpus callosum, by the basal ganglia (caudate and claustrum) or by the cerebellum, based also upon previously published data (Glickstein, 2000).

Currently, three different views on essential tremor are under debate: abnormal oscillations within the tremor network, progressive cell loss in the frame of a neurodegenerative disorder or a localized GABAergic dysfunction (Gironell *et al.*, 2012; Sharifi *et al.*, 2014). We do believe that these recent findings provided both by Archer *et al.* (2018) and by our group (Tuleasca *et al.*, 2018a) open

new gates in understanding of the pathophysiology of essential tremor. As we suggested, they might have clinical implications for interventional studies, such as thalamotomy.

The discussion of the appropriate target for tremor remains opened, although the VIM or the PSA are classically considered. In both our VBM reports published earlier (Tuleasca *et al.*, 2017b, 2018a), we proposed that if indeed the visual networks are involved in tremor arrest, this raises the question of a requirement to potentially recruit them in the surgical targeting. This issue remains to be debated and should be discussed in the frame of further studies, with larger cohorts, reproducing both findings from structural (VBM) and functional (task-based and resting-state) MRI. Furthermore, randomized controlled trials should provide evidence for a targeting refinement, including parts of visual areas, as we advocated, for standard electrical stimulation and/or VIM radiosurgery or HIFU. Ultimately, this might lead to eventual safer, less expensive and more effective methods of neuro-enhancement and further turn decades of hard work into real-life benefits.

Acknowledgements

Lausanne and Marseille University Hospitals.

Funding

The work was supported in part by the Swiss National Science Foundation (SNSF-205321-157040); in part by the CHU Timone, Marseille, France; and in part by the Centre d'Imagerie BioMédicale (CIBM) of the Universities of Lausanne and Geneva, the Ecole Polytechnique Fédérale de Lausanne, the Centre Hospitalier Universitaire Vaudois, the Hôpitaux Universitaires de Genève, and the Leenaards and Jeantet Foundations.

References

Archer DB, Coombes SA, Chu WT, Chung JW, Burciu RG, Okun MS, et al. A widespread visually-sensitive functional network relates to symptoms in essential tremor. *Brain* 2018; 141: 472–85.

Beckmann C, DeLuca M, Devlin J, Smith S. Investigations into resting-state connectivity using independent component analysis. *Philos Trans R Soc Lond B Biol Sci* 2005; 360: 1001–13.

Benabid AL, Pollak P, Gao D, Hoffmann D, Limousin P, Gay E, et al. Chronic electrical stimulation of the ventralis intermedius nucleus of the thalamus as a treatment of movement disorders. *J Neurosurg* 1996; 84(2): 203–14.

Blomstedt P, Sandvik U, Tisch S. Deep brain stimulation in the posterior subthalamic area in the treatment of essential tremor. *Mov Disord* 2010; 25: 1350–6.

Calhoun VD, Adali T, Pearlson GD, Pekar JJ. A method for making group inferences from functional MRI data using independent component analysis. *Hum Brain Mapp* 2001; 14: 140–51.

Elias WJ, Lipsman N, Ondo WG, Ghanouni P, Kim YG, Lee W, et al. A randomized trial of focused ultrasound thalamotomy for essential tremor. *N Engl J Med* 2016; 375: 730–9.

Fahn S, Tolosa E, Marin C. Clinical rating scale for tremor. *Parkinson's disease and movement disorders*. Baltimore: Urban and Schwarzenberg; 1988. p. 225–34.

Fox MW, Ahlskog JE, Kelly PJ. Stereotactic ventrolateralis thalamotomy for medically refractory tremor in post-levodopa era Parkinson's disease patients. *J Neurosurg* 1991; 75: 723–30.

Fyttagoridis A, Sandvik U, Astrom M, Bergenheim T, Blomstedt P. Long term follow-up of deep brain stimulation of the caudal zona incerta for essential tremor. *J Neurol Neurosurg Psychiatry* 2012; 83: 258–62.

Gironell A, Figueiras FP, Pagonabarraga J, Herance JR, Pascual-Sedano B, Trampal C, et al. Gaba and serotonin molecular neuroimaging in essential tremor: a clinical correlation study. *Parkinsonism Relat Disord* 2012; 18: 876–80.

Glickstein M. How are visual areas of the brain connected to motor areas for the sensory guidance of movement? *Trends Neurosci* 2000; 23: 613–7.

Kelly RM, Strick PL. Cerebellar loops with motor cortex and prefrontal cortex of a nonhuman primate. *J Neurosci* 2003; 23: 8432–44.

Regis J, Carron R, Park M. Is radiosurgery a neuromodulation therapy? A 2009 Fabrikant award lecture. *J Neurooncol* 2010; 98: 155–62.

Schuurman PR, Bosch DA, Bossuyt PM, Bonsel GJ, van Someren EJ, de Bie RM, et al. A comparison of continuous thalamic stimulation and thalamotomy for suppression of severe tremor. *N Engl J Med* 2000; 342: 461–8.

Sharifi S, Nederveen AJ, Booij J, van Rootselaar AF. Neuroimaging essentials in essential tremor: a systematic review. *Neuroimage Clin* 2014; 5: 217–31.

Tuleasca C, Najdenovska E, Régis J, Witjas T, Girard N, Champoudry J, et al. Clinical response to Vim's thalamic stereotactic radiosurgery for essential tremor is associated with distinctive functional connectivity patterns. *Acta Neurochir* 2018a; 160: 611–24. DOI: 10.1007/s00701-017-3456-x. (published online <https://link.springer.com/journal/701/onlineFirst/page/1>)

Tuleasca C, Pralong E, Najdenovska E, Cuadra MB, Marques JRF, Vingerhoets F, et al. Deep brain stimulation after previous gamma knife thalamotomy of the Vim for essential tremor is feasible! Clinical, electrophysiological and radiological findings. *Acta Neurochir* 2017a; 159: 1371–3.

Tuleasca C, Witjas T, Najdenovska E, Verger A, Girard N, Champoudry J, et al. Assessing the clinical outcome of Vim radiosurgery with voxel-based morphometry: visual areas are linked with tremor arrest! *Acta Neurochir* 2017b; 159: 2139–44.

Tuleasca C, Witjas T, Van de Ville D, Najdenovska E, Verger A, Girard N, et al. Right Brodmann area 18 predicts tremor arrest after Vim radiosurgery: a voxel-based morphometry study. *Acta Neurochir* 2018b; 160: 603–9.

Witjas T, Carron R, Krack P, Eusebio A, Vaugoyeau M, Hariz M, et al. A prospective single-blind study of Gamma Knife thalamotomy for tremor. *Neurology* 2015; 85: 1562–8.