

White matter changes in Lipopolysaccharide treated fetal sheep measured by high-field Diffusion Tensor Imaging

Y. van de Looij^{1,2}, J. M. Dean³, G. Lodygensky¹, H. Hagberg³, P. S. Hüppi¹, C. Mallard³, R. Gruetter^{2,4}, and S. V. Sizonenko¹

¹Division of Child Growth & Development, Department of Pediatrics, University of Geneva, Geneva, Switzerland, ²Laboratory for Functional and Metabolic Imaging, Ecole Polytechnique Fédérale de Lausanne, Lausanne, Switzerland, ³Perinatal Center, Department of Neuroscience and Physiology, University of Gothenburg, Göteborg, Sweden, ⁴Department of Radiology, University of Geneva and Lausanne, Switzerland

Introduction:

White matter (WM) injury is a major cause of developmental disabilities in up to 75% infants after preterm birth. Injury typically affects periventricular WM. In those infants, hypoxemia and inflammation are the two main causes of WM damage. Inflammatory brain injury model can be achieved by bacteria-derived lipopolysaccharide (LPS) exposure. Diffusion tensor imaging (DTI) derived parameters as directional diffusivities (D_{\parallel} and D_{\perp}) and Fractional Anisotropy (FA) are commonly used to probe brain microstructure. The goal of this study was to characterize changes in the fetal sheep brain following fetal LPS exposure by electroencephalography (EEG), DTI derived parameters and neuropathology.

Material and Methods:

Fetal sheep at 70% of gestation received vehicle (control, n=7) or LPS (200ng; n=7) at 103d gestation (term = 145d). EEG was continuously recorded on a BrainZ clinical monitor. Fetal brains were collected after 10d recovery and formalin-fixed for subsequent ex-vivo MRI. All experiments were performed on an actively-shielded 9.4T/31cm magnet (Varian/Magnex) equipped with 12-cm gradient coils (400mT/m, 120 μ s) with a transceive 50-mm container volume RF coil. First and second order shims were manually adjusted, with water linewidth ranged between 100 to 150 Hz. Spin Echo sequence with addition of the Stejskal-Tanner diffusion gradients was used. Diffusion gradients were applied along the six directions of the Dual diffusion gradient sampling scheme [1] as well as the six opposite directions to cancel b-value cross terms [2]. The b-value was set to 1997 s.mm⁻² ($G_{\text{diff}} = 15$ G/cm, $\delta = 6$ ms and $\Delta = 19$ ms). Image acquisition parameters were: FOV = 50 \times 50 mm² for a matrix size of 256 \times 256 (in-plane pixel size = 195 μ m). 54 slices of 1 mm thickness were acquired in the coronal plane. Scan were averaged 2 times with TE/TR = 35/11000 ms. Using a homemade Matlab (Mathworks, Natick, MA) software, D_{\parallel} and D_{\perp} as well as FA was derived from the tensor. Two different regions were analyzed in the sheep brain: the corpus callosum (CC) and the periventricular white matter (PVWM). Data were measured on three different ROIs in the anterior, the median and the posterior levels of the sheep brain. Total brain volume measurement was performed using BrainVisa/Anatomist [3]. The brains were subsequently sectioned (10 μ m thick) and stained with acid fuchsin/thionin (AF/T) for assessment of white matter/grey matter injury.

Results:

In the LPS group, there was a small, but significant decrease in EEG amplitude from 3-4h post LPS ($p < 0.05$; nadir 11.5 \pm 0.1 μ V LPS group vs. 13.5 \pm 1.3 μ V control group; Repeated measures ANOVA). EEG amplitude then returned to control group levels up to 192h post LPS, after which EEG was significantly less than in the control group for the remainder of the experiment ($p < 0.05$). At post mortem, brain weight in the LPS group was significantly less than in the control group ($p < 0.05$; LPS 22.7 \pm 0.6 g vs. sham 25.0 \pm 0.6 g; t-test). FA values in the LPS group were significantly lower than controls in the CC and PVWM (CC: anterior 0.67 \pm 0.08 vs. 0.86 \pm 0.06 $p = 0.002$, middle 0.55 \pm 0.08 vs. 0.66 \pm 0.04 $p = 0.001$, and posterior 0.76 \pm 0.05 vs. 0.85 \pm 0.04 $p = 0.001$; PVWM: posterior 0.61 \pm 0.11 vs. 0.78 \pm 0.08 $p = 0.01$; Mann-Whitney test). FA in the PVWM anterior and middle slices showed a tendency to be decrease in the LPS group ($p = 0.053$). Total brain volume was found significantly lower in the LPS group compared with control (24.4 \pm 1 cm³ and 26.1 \pm 0.8 cm³ respectively, $p = 0.01$; Mann-Whitney test). AF/T staining provided evidence for WM disruption around the lateral ventricles of animals exposed to LPS.

Discussion and conclusion:

LPS infusion resulted in a mild but transient EEG suppression, then 8-10d after LPS a persistent drop in EEG amplitude was observed, providing evidence for persisting cerebral alterations. Reduced FA revealed alterations in developing white matter after fetal exposure to LPS prior to the onset of myelination. This FA reduction is due to a significant increase of D_{\perp} in the LPS white matter i.e. an increased water mobility perpendicular to the mean direction of diffusion, probably due to lesions and/or abnormal development of white matter following LPS exposure. This result is correlated by histopathological evidence of periventricular white matter injury (Figure 1). Persisting cerebral alterations on MRI are supported by chronic EEG suppression, brain volume decrease and brain weight reduction at postmortem. This work provides evidence of white matter injuries following LPS detectable by DTI. Histopathological analysis and brain volume segmentation are still in progress to understand the physiopathology of these microstructure modifications and their correlation with MRI. This study could be of interest for clinical strategy in human preterm infants.

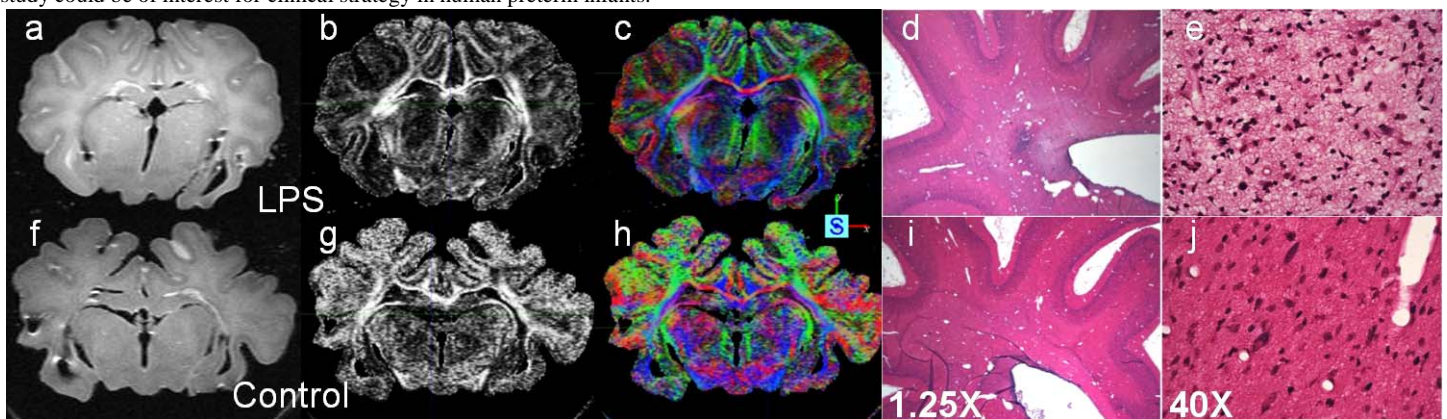


Figure 1: T₂W images (a,f), FA (b,g) and direction encoded color maps (c,h) of a typical LPS (up) and Control (down) sheep brain. T₂W images show a probable abnormal development in the LPS (a) compared with control (f). AF/T staining of the same animal, LPS (d,e) and Control (i,j). Staining provide evidence of WM disruption around the lateral ventricles of animals exposed to LPS (d,e).

References: [1] Bassler PJ. et al. MRM 1998; [2] Madi S. et al. MRM 2005; [3] Cointepas Y. et al. Neuroimage 2001.

Acknowledgements: Supported by NEOBRAIN Consortium, European Commission, the Centre d'Imagerie Biomédicale (CIBM) of the UNIL, UNIGE, HUG, CHUV, EPFL, the Leenards and Jeantet Foundation and the Fond National Suisse, Switzerland.