

Stroke

American Stroke
AssociationSM

A Division of American
Heart Association



JOURNAL OF THE AMERICAN HEART ASSOCIATION

Early Predictive Biomarkers for Lesion After Transient Cerebral Ischemia

Carole Berthet, Hongxia Lei, Rolf Gruetter and Lorenz Hirt

Stroke published online Feb 3, 2011;

DOI: 10.1161/STROKEAHA.110.603647

Stroke is published by the American Heart Association, 7272 Greenville Avenue, Dallas, TX 72514
Copyright © 2011 American Heart Association. All rights reserved. Print ISSN: 0039-2499. Online
ISSN: 1524-4628

The online version of this article, along with updated information and services, is
located on the World Wide Web at:

<http://stroke.ahajournals.org>

Subscriptions: Information about subscribing to *Stroke* is online at
<http://stroke.ahajournals.org/subscriptions/>

Permissions: Permissions & Rights Desk, Lippincott Williams & Wilkins, a division of Wolters
Kluwer Health, 351 West Camden Street, Baltimore, MD 21202-2436. Phone: 410-528-4050. Fax:
410-528-8550. E-mail:
journalpermissions@lww.com

Reprints: Information about reprints can be found online at
<http://www.lww.com/reprints>

Early Predictive Biomarkers for Lesion After Transient Cerebral Ischemia

Carole Berthet, PhD*; Hongxia Lei, PhD*; Rolf Gruetter, PhD; Lorenz Hirt, MD

Background and Purpose—Despite the improving imaging techniques, it remains challenging to predict the outcome early after transient cerebral ischemia. The aim of this study was thus to identify early metabolic biomarkers for outcome prediction.

Methods—We modeled transient ischemic attacks and strokes in mice. Using high-field MR spectroscopy, we correlated early changes in the neurochemical profile of the ischemic striatum with histopathologic alterations at a later time point.

Results—A significant increase in glutamine was measured between 3 hours and 8 hours after all ischemic events followed by reperfusion independently of the outcome and can thus be considered as an indicator of recent transient ischemia. On the other hand, a reduction of the score obtained by summing the concentrations of N-acetyl aspartate, glutamate, and taurine was a good predictor of an irreversible lesion as early as 3 hours after ischemia.

Conclusions—We identified biomarkers of reversible and irreversible ischemic damage, which can be used in an early predictive evaluation of stroke outcome. (*Stroke*. 2011;42:799-805.)

Key Words: biological markers ■ magnetic resonance spectroscopy ■ middle cerebral artery occlusion ■ transient ischemic attack ■ stroke

The course of ischemic episodes is very variable and it is difficult to predict the outcome of an individual patient early after ischemia and particularly early after reperfusion. A better prediction of the outcome at early time points would greatly facilitate clinical decisions. Moreover, this would help to distinguish transient ischemic attacks (TIAs) from stroke, refine patient selection for neuroprotection trials, and eventually help to identify patients more likely to benefit from future neuroprotective approaches.

Several cerebral imaging techniques are available for the diagnosis and management of patients with stroke.¹ At late time points, the established lesion can be visualized both by T2-weighted images and CT. At early time points, before reperfusion, perfusion CT or perfusion-weighted MR images are used to measure perfusion and allow an estimation of damaged tissue and tissue at risk.² Diffusion-weighted MR images (DWI), and to some extent diffusion tensor imaging, monitor disturbances of ion homeostasis, water distribution, and tissue microstructure. The apparent diffusion coefficient (ADC) measured from DWI decreases immediately after the onset of ischemia and its decrease is proportional to the severity of ischemia.³ A combination of DWI and perfusion-weighted MR imaging techniques is used to detect tissue at risk where perfusion is decreased but water diffusion is still

normal.³ These techniques convey a good spatial resolution, are highly sensitive, and give information on the localization and extent of the lesion, but the estimation of the severity of ischemia is not very reliable inasmuch as DWI hyperintensities are often reversible.⁴ Moreover, detection of only half of the TIAs is possible even when using a combination of DWI and perfusion-weighted imaging.⁵ Similarly, in animal models, transient ischemia cannot be detected using T2-weighted images, perfusion-weighted images, nor DWIs during the first hours after reperfusion.⁶

Another NMR technique, MR spectroscopy (MRS), can give information on the severity of ischemic injury by measuring metabolites after cerebral ischemia. In particular, a decrease in N-acetyl-aspartate (NAA) has been shown to correlate with neuronal loss,⁷ which was expanded to predict outcome after stroke⁸⁻¹⁰ and traumatic brain injury.¹⁰ Recent studies in ischemic mice or patients with traumatic brain injury^{11,12} showed important metabolite concentration changes in areas or at time points (between 3 and 24 hours) in which no abnormality could be detected by MRI, suggesting that MRS could detect early tissue damage or compromised cell function. Therefore, the aim of the present study was to identify neurochemical markers for transient cerebral ischemia and outcome prediction at very early time points

Received September 23, 2010; final revision received October 13, 2010; accepted October 26, 2010.

From the Department of Clinical Neurosciences (C.B., L.H.), Centre Hospitalier Universitaire Vaudois, Lausanne, Switzerland; the Laboratory of Functional and Metabolic Imaging (H.L., R.G.), Ecole Polytechnique Fédérale de Lausanne, Lausanne, Switzerland; the Department of Radiology (H.L., R.G.), University of Lausanne, Lausanne, Switzerland; and the Department of Radiology (R.G.), University of Geneva, Geneva, Switzerland.

The online-only Data Supplement is available at <http://stroke.ahajournals.org/cgi/content/full/STROKEAHA.110.603647/DC1>.

*C.B. and H.L. contributed equally to this work.

Correspondence to Hongxia Lei, PhD, Laboratory for Functional and Metabolic Imaging, Ecole Polytechnique Fédérale de Lausanne, 1015 Lausanne, Switzerland. E-mail hongxia.lei@epfl.ch

© 2011 American Heart Association, Inc.

Stroke is available at <http://stroke.ahajournals.org>

DOI: 10.1161/STROKEAHA.110.603647

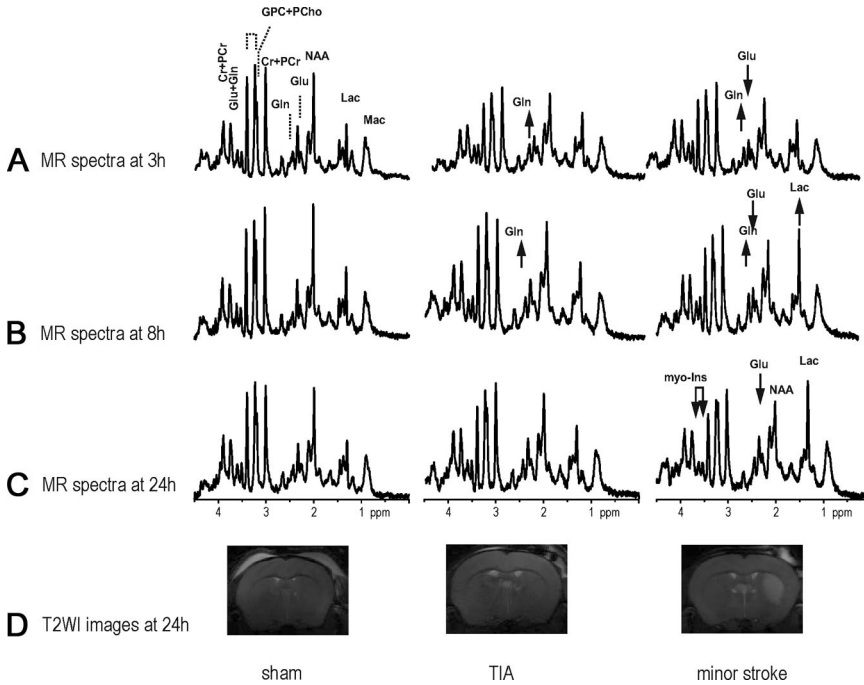


Figure 1. The 2 10-minute middle cerebral artery occlusion (MCAO) subgroups have different MR spectra at all measured time points. Evolution of MR spectra over time and T2-weighted images at 24 hours. Each column corresponds to a representative mouse from each group (sham, TIA, minor stroke). Each row shows typical measurements of ¹H-MR spectra at 3 hours (A), 8 hours (B), and 24 hours (C) or T2-weighted images at 24 hours after ischemia (D) of the same mouse. All spectra were scaled relative to the heights of the phosphocreatine+creatine and macromolecule peaks in the spectrum of the sham operated group at 3 hours (A). Arrows show the apparent changes in the spectra from both 10-minute tMCAO groups compared with sham-operated animals. Cr indicates creatine; Gln, glutamine; Glu, glutamate; GPC, glycerophosphocholine; Lac, lactate; Mac, macromolecules; myo-Ins, myo-inositol; PCho, phosphocholine; PCr, phosphocreatine; Tau, taurine; T2WI, T2-weighted images.

after reperfusion when neither T2 hyperintensities nor abnormal water diffusion are detectable by MRI.

Methods

All animal experiments were conducted in accordance with the guidelines of and with approval of the cantonal veterinary office.

Transient Middle Cerebral Artery Occlusion in the Mouse

For MR studies, 29 male ICR-CD1 mice (20 to 33 g; Charles River, L'Arbresle, France) underwent transient middle cerebral artery occlusion (tMCAO) as described previously.¹² Briefly, mice were anesthetized and maintained under 1.5% to 2% isoflurane in 30% oxygen and 70% nitrous oxide using a face mask. At 0 hour,

ischemia was induced by inserting a silicone-coated nylon filament (diameter: 0.17 mm; Doccol Co, Redlands, CA) through the left common carotid artery into the internal carotid artery. The filament was withdrawn after 10 minutes allowing reperfusion. Regional cerebral blood flow was measured throughout the entire operation by a laser-Doppler flowmetry (Periflux 5000; Perimed) with a flexible probe fixed on the skull, 2 mm posteriorly and 6 mm laterally from the bregma. The average regional cerebral blood flow of included mice was 15%±5% (no lesion) and 14%±4% (lesion) of the baseline level during ischemia and 74%±16% (no lesion) and 74%±20% (lesion) of the baseline after reperfusion. Throughout surgery and until awaking, the rectal temperature was maintained at 37±0.5°C with a temperature control unit (FHC Inc).

Mice were euthanized 30 hours after ischemia. Among these mice, 4 were excluded due to unsatisfactory ischemia or spectral quality (2

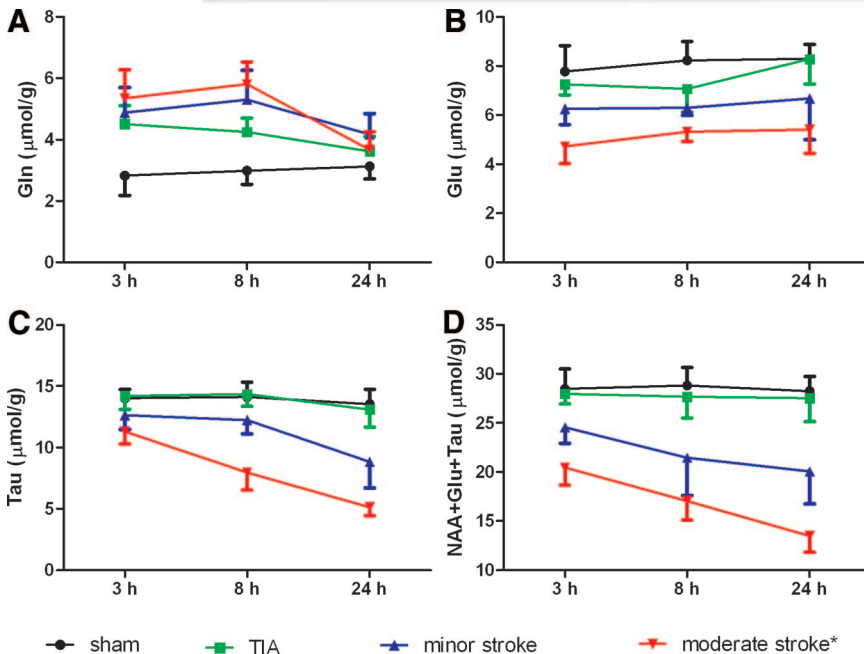


Figure 2. Evolution over time of some metabolites involved in the developing lesion after ischemia. The moderate stroke group is described in a recent publication.¹² (A) Glutamine (Gln), (B) glutamate (Glu), (C) taurine (Tau), (D) N-acetyl aspartate+glutamate+taurine (NAA+Glu+Tau). Error bars reflect SD.

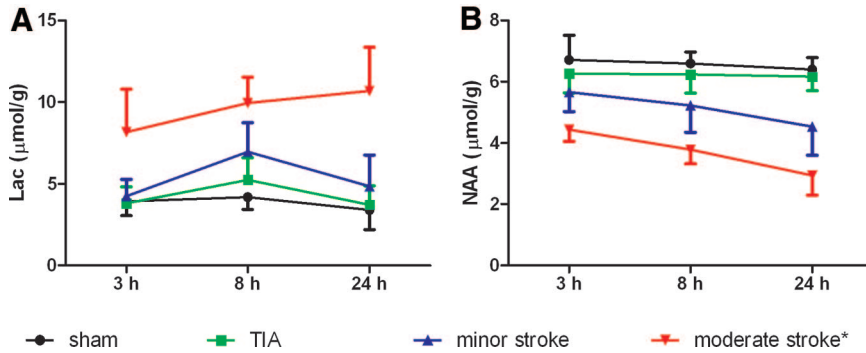


Figure 3. Evolution over time of metabolites widely used in predicting lesion after ischemia. *The moderate stroke group is described in a recent publication.¹² (A) lactate (Lac), (B) N-acetyl aspartate (NAA). Error bars reflect SD.

mice) and 9 were used for histological characterization at 3 hours, 8 hours, and 24 hours after ischemia. In addition, 7 mice (24 to 34 g) of the sham group underwent the same procedure without any artery ligation.

Neurological Deficits

Mice were observed before euthanasia to evaluate their neurological deficit. Their neuroscore was graded as previously described¹³ (0, no observable neurological deficit; 1, failure to extend the right fore-paw; 2, circling to the contralateral side; and 3, loss of walking or righting reflex).

Determination of Ischemic Lesion Volumes

Animals were euthanized by intracardiac paraformaldehyde (4% in phosphate-buffered saline) perfusion. Brains were postfixed overnight in 4% paraformaldehyde and cryoprotected in 30% sucrose for 48 hours before freezing. 20-μm-thick, 700-μm distant, coronal cryostat sections were prepared. Lesion size was determined on cresyl violet-stained sections and MR images as described previously.¹²

In Vivo MR Studies

MR studies were carried out in a horizontal, 14.1-T/26-cm magnet (Magnex Scientific, Abingdon, UK) with a 12-cm inner-diameter gradient (400 mT/m in 200 μs, minimized eddy currents) interfaced to a DirectDrive console (Varian Inc, Palo Alto, CA). A home-built quadrature surface coil with 2 geometrically decoupled single turn loops (12 mm inner diameter) resonating at 600-MHz radiofrequency was used for radiofrequency transmission and reception at 14.1-T as described previously.¹²

MR Imaging

Multislice (20×0.6-mm slices) T2-weighted coronal images were acquired using the fast spin echo technique¹⁴ with effective echo time TE_{eff}=50 ms and repetition time TR=6000 ms to locate the volume of interest in the left striatum and evaluate the development of ischemic lesions at 24 hours postischemia.

Four of the 10-minute middle cerebral artery occlusion mice were randomly selected and underwent DWI measurement at 3 hours postischemia. Diffusion tensor images were acquired for calculating the ADC maps using segmented (4 shots) semiadiabatic double spin echo echoplanar imaging¹⁵ (RO×PE=23×15 mm², 128×64 data matrix) with additional diffusion gradients (G_{diff}=21 G/cm, δ=3ms, Δ=20 ms, and giving a b-value of 1079 s/mm²) along 7 dimensions. Five of 0.8-mm-thickness contiguous coronal slices were acquired with TE/TR=42.5/2000 ms and 7 averages. Nyquist ghosts were minimized by adopting a previously described “negative readout gradient” strategy.¹⁶ The total scan time was 17 minutes.

MR Spectroscopy

Field inhomogeneities were adjusted over the volume of interest using the echoplanar version of FASTMAP¹⁷ and resulted in water line widths within 30 Hz for 6 to 8 μL volumes. Localized ¹H nuclear MR spectra were obtained for each animal at 3 hours, 8

hours, and 24 hours using the SPECIAL technique¹⁸ (echo/repetition time=2.8/4000 ms, 240 to 320 averages) in combination with outer volume suppression and VAPOR water suppression,¹⁹ resulted in the acquired MR spectra with satisfactory signal-to-noise ratios (15±3) and excellent metabolic line widths (18±4 Hz, 10 to 30 Hz).

Quantification

ADC maps were derived from the acquired diffusion tensor images for 2 regions of interest, that is, ipsilateral and contralateral striatal tissue using Matlab.

The in vivo ¹H-MR spectra were processed as described in Lei et al.¹² Absolute quantification was obtained using a linear combination analysis method, Linear Combination of Model Spectra (LC-Model)²⁰ assuming 80% brain water content (100% visibility of water signal and 55.5 mol/L molarities).

Statistics

All data are presented as mean±SD, except neurological scores (median [minimum, maximum]). Significance was set as P<0.05 using the Mann-Whitney test to compare lesion size measured by MRI and histologically, the Kruskal-Wallis test followed by Dunn multiple-comparison test for neuroscore comparisons, the Student *t* test for ADC measurements, and Pearson *r* test to correlate final lesion size to metabolite concentrations (GraphPad Prism 5).

Results

Characterization of Degrees of Ischemic Severity in Mice

The design of the present study was to compare animals below and above the threshold for irreversible ischemic

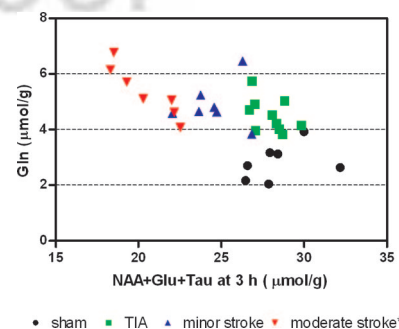


Figure 4. A combination of 4 metabolites at 3 hours allows a very good separation among the 4 groups. Glutamine (Gln) is increased in all ischemic conditions with reperfusion independently of the outcome. A combined score obtained by adding the concentrations of N-acetyl-aspartate, glutamate, and taurine (NAA+Glu+Tau) at 3 hours identifies the animals that will develop a lesion later on. *The moderate stroke group is taken from our recent publication.¹² The scatter plot of NAA+Glu+Tau versus Gln allows very good separation among the 4 experimental groups.

lesions to find biomarkers for outcome prediction. We noticed that in our model, 10 minutes of ischemia produced small striatal lesions in half the mice only, indicating that this ischemia duration lies at this threshold. These mice were divided into 2 groups depending on the presence ($n=7$) or absence ($n=10$) of a lesion on T2-weighted MR images at 24 hours. These mice were compared with sham-operated and 30-minute tMCAO mice. All animals were euthanized 30 hours after ischemia onset for histology and lesion size determination (Supplemental Figure I, available at <http://stroke.ahajournals.org>). Small lesions were detected 30 hours after 10 minutes tMCAO ($3.3 \pm 2.9 \text{ mm}^3$) in the lesion 10-minute tMCAO group consistent with the lesion size measured at 24 hours on MR images of $8.3 \pm 3.5 \text{ mm}^3$. The slight difference in lesion size between MRI and Nissl staining ($P=0.026$, 2-tailed Mann-Whitney test) probably results from a small overestimation of the lesion size by MRI due to edema or to the 6-hour difference between these measurements. It is consistent with similar previously observed differences.¹²

The neuroscore determined at 30 hours was not significantly different between no lesion 10-minute tMCAO (0 [0 to 0.5]) and lesion 10-minute tMCAO (0 [0 to 1]) but between both of them and 30-minute tMCAO (1 [0.5 to 2]); $P<0.01$ and $P<0.05$, respectively, using Kruskal-Wallis followed by Dunn multiple comparison test). There was complete recovery of the neurological deficit at 30 hours in almost all animals in our “no lesion” tMCAO group and no lesion was detected by MRI. The short ischemia in this group therefore corresponds to TIAs according to the new definition proposed by Easton et al.²¹ We thus called it the “TIA group.” Similarly, we called the 10-minute tMCAO group with lesion the “minor stroke” group and the 30-minute tMCAO “moderate stroke” group.

MR Assessments of Metabolic Evolution After Ischemia

At 3 hours after transient ischemia, there was no detectable signal change in any group on either T2-weighted images or on ADC maps ($6.82 \pm 0.19 \times 10^{-4} \text{ mm}^2/\text{s}$ in ipsilateral striatum versus $6.85 \pm 0.24 \times 10^{-4} \text{ mm}^2/\text{s}$ in contralateral striatum with $P=0.80$ by paired Student t test). On the contrary, several changes were apparent in the spectra of both TIA and minor stroke groups (Figure 1) as early as 3 hours after ischemia: increased glutamine was observed in both groups, which was accompanied by a decrease in glutamate only in the minor stroke group. The metabolic profile of the sham-operated mice did not vary. In mice that were developing a lesion, additional metabolite changes appeared at 8 hours (increased lactate) and 24 hours (decreased NAA and myo-inositol), whereas the neurochemical profile of the TIA group almost normalized at 24 hours.

Neurochemical Changes Can Be Used to Characterize the Severity of Transient Ischemic Insults

The visually noticeable MR spectra changes were confirmed by quantitative measurements of the neurochemical profiles (Figures 2 and 3; Supplemental Figure II), which further

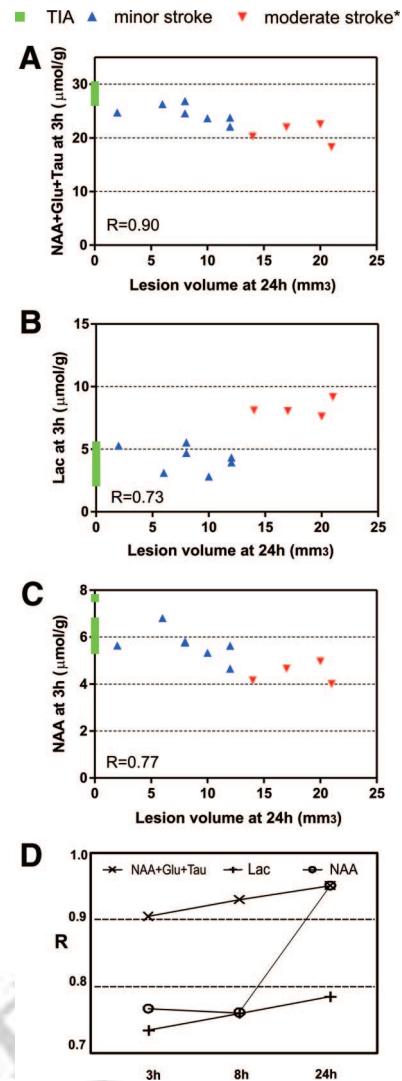


Figure 5. The cumulative score of N-acetyl-aspartate+glutamate+taurine is in good correlation with the final lesion size. Correlation of selected metabolites at each time point with the ischemic lesion at 24 hours. At 3 hours, only the combination of N-acetyl-aspartate+glutamate+taurine (NAA+Glu+Tau) allows a good correlation (calculated with Pearson r test) with final lesion size, whereas the other correlations (lactate, NAA) get better with time. *The moderate stroke group is taken from our recent publication.¹² (A) NAA+Glu+Tau at 3 hours, (B) lactate (Lac) at 3 hours, (C) NAA at 3 hours, (D) summary of the correlation coefficients of NAA+Glu+Tau, Lac and NAA at 3, 8, and 24 hours in absolute values. The “R” stands for the absolute value from Pearson r test.

revealed additional changes. The increase in glutamine 3 hours after ischemia was a common hallmark of all transient ischemic episodes regardless of the duration. It returned to basal levels more quickly in the absence of a lesion (Figure 2A; Supplemental Figure II).¹² On the other hand, glutamate, NAA, and taurine were significantly decreased as early as 3 hours after the insult only in animals with irreversible damage (Figures 2B–C and 3B; Supplemental Figure II). We summed the concentrations of these 3 metabolites and noted that this composite score separated mice that will develop a lesion or not (Figure 2D), whereas lactate or NAA concentrations were unable to separate them before 8 hours (Figure 3A–B).

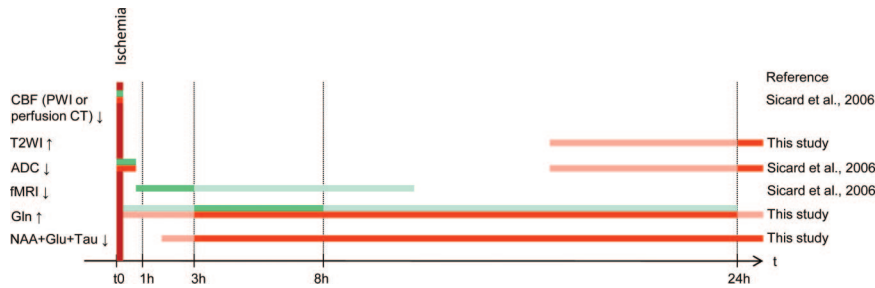


Figure 6. MRS is the only noninvasive diagnostic method able to determine if cerebral tissue has suffered from ischemia and to predict its outcome between 1 hour and 8 hours after ischemia. Green (short ischemia without lesion) and orange bars (short ischemia with lesion) represent the period when an abnormality can be detected with the corresponding technique. Lighter bars represent expected detection in need to be tested. CBF indicates cerebral blood flow; fMRI, functional MRI; Gln, glutamine; Glu, glutamate; PWI, perfusion-weighted imaging; T2WI, T2-weighted images; Tau, taurine.

Scatterplotting the NAA+glutamate+taurine score against the glutamine concentration at 3 hours (Figure 4) allowed excellent separation of the 4 conditions with nearly no overlap, especially between the TIA and stroke groups. After 3 hours of permanent ischemia (Supplemental Figure III), the metabolism is different, showing a decrease of glutamine instead of an increase. However, the composite score of NAA+glutamate+taurine is also decreased, indicating that a lesion will develop. It is thus also a good predictor in the absence of reperfusion.

Neurochemical Changes Predict Ischemic Lesion Size

The correlations between lactate or NAA at 3 hours and MRI lesions at 24 hours ($R=0.73$ and $R=0.77$, respectively, absolute values from Pearson r test; Figure 5B–C) were found to be less precise than the correlation between NAA+glutamate+taurine at 3 hours and the resulting lesion size at 24 hours ($R=0.90$; Figure 5A). Even if, at later time points, the prediction of lesion size with lactate ($R=0.76$ at 8 hours and $R=0.78$ at 24 hours; Figure 5D) and NAA ($R=0.76$ at 8 hours and $R=0.95$ at 24 hours; Figure 5D) becomes more accurate, the sum of NAA+glutamate+taurine remains the best predictor up to 8 hours ($R=0.87$; Figure 5D) and is similar to NAA at 24 hours ($R=0.97$; Figure 5D).

Discussion

By measuring 19 neurochemical constituents in the mouse striatum 3 and 8 hours after cerebral ischemia of varying intensity, we have shown that ^1H MRS highlights metabolic changes reflecting a recent transient ischemia and predicts the outcome at 24 hours. Ischemia triggered a transient increase in glutamine after reperfusion independent of its severity, whereas irreversibly damaged tissue was characterized by a significant decrease in NAA, glutamate, and taurine independently of reperfusion. To our knowledge, this is the first time that predictive biomarkers of cerebral ischemia have been described at an early time point when no abnormality can be detected with standard and widely used clinical MRI techniques.^{6,22}

It is remarkable to see that the only metabolic change common to all ischemic conditions after reperfusion is increased glutamine, which we previously hypothesized to result from the transformation of excitotoxic glutamate by

astrocytes after restoration of energy supplies.¹² Our observation of reduced glutamine levels 3 hours after permanent ischemia (Supplemental Figure III) supports this hypothesis. Thus, the elevated glutamine can be used as a biomarker of reperfused ischemia at an early time point.

Of the more established metabolic changes after ischemia, it is well known that the NAA concentration correlates well with observed ischemic lesion size and extent of neuronal death.^{8–10,23,24} However, this cannot be reliably correlated earlier than 8 to 24 hours after ischemia (Figure 4) probably because neuronal death is a gradual process after mild to moderate ischemia. In addition to NAA, increased lactate is a hallmark of ischemia^{23,25,26} that has been described in patients with TIAs.^{27,28} However, the early measurements in the present study (showing no change in lactate concentration after 10 minutes middle cerebral artery occlusion) suggest that lactate may not reliably identify ischemic episodes or predict ischemic outcome. The difference in lactate concentrations between patients with TIA and our 10-minute ischemic mice might be due to the time of ^1H MRS measurements, which were performed >1 day after the attack in the human studies. Moreover, the lactate profile is complex with 2 episodes of lactate accumulation,²⁹ and probably lactate content at early stages does not reliably predict the outcome.

In addition, 2 further metabolites mainly linked to neuronal metabolism and strongly involved in ischemia,^{8–10,23,24,30} glutamate and taurine, decreased in the minor stroke group. The glutamate decrease is consistent with the well-known glutamate release from neurons during ischemia, which is then taken up by astrocytes and either transformed to glutamine or oxidized after reperfusion.³¹ On the other hand, taurine is thought to be neuroprotective by both acting on osmoregulation³² and neuromodulation.³³ Recently, Saransaari and Oja³⁰ have shown that taurine release in ischemia is modulated by glutamate receptors, which may explain the correlation between taurine decrease and severity of ischemia. Importantly, the final ischemic lesion stands in excellent correlation with our cumulative score of NAA+glutamate+taurine not only at 24 hours, but also as early as 3 hours and 8 hours (Figure 5). Therefore, this combination score is well adapted for the prediction of ischemia severity.

The highly predictive power of these biomarkers in animal models now needs testing in human patients with TIA and

stroke. Indeed, our goal is to test if MRS biomarkers could be used for early diagnosis for treatment optimization. The distinction between TIA and stroke is an important but difficult question based on the definition of TIA. The biomarkers described in this study could help distinguish between TIA and stroke only if we use the new definition of TIA.²¹ In any case, both patients with TIA and those with stroke have to be observed in the hospital. The importance of the biomarkers will be to help determine if a patient with an acute neurological deficit will later develop a lesion and thus if neuroprotective treatment is needed. Moreover, the observation of glutamine increase in patients with TIA can help determine which areas had a lack of perfusion. The advantage of MRS compared with routinely used imaging techniques³⁴ is its capacity to identify recent ischemic events and predict outcome in the first hours after reperfusion, at a time when none of the other techniques detect any abnormality (Figure 6) and where diagnostic blood biomarkers are less precise.³⁵

In conclusion, the ability to identify ischemic damage and predict the outcome (neuronal loss or recovery) based on metabolite concentrations between 3 and 8 hours after ischemia opens exciting perspectives for stroke diagnosis and treatment. Given that the biomarkers described in this study can also be measured in humans using clinical 3-T MR equipment,³⁶ ¹H-MRS could thus provide critical information for the evaluation and diagnosis in patients with stroke and TIA.

Acknowledgments

We thank Dr Melanie Price for critically reading the article and Dr Yohan van de Looij and Mr Nicolas Kunz for setting up the ADC measurements.

Sources of Funding

This work was supported by the Centre d'Imagerie BioMédicale of the University of Lausanne (UNIL), University of Geneva (UNIGE), Hôpital universitaire de Genève (HUG), Centre Hospitalier Universitaire Vaudois (CHUV), and Ecole Polytechnique Fédérale de Lausanne (EPFL); and the Leenaards, Jeantet and Gianni Biaggi de Blasys Foundations.

Disclosures

None.

References

- Sanak D, Horak D, Herzig R, Hlustik P, Kanovsky P. The role of magnetic resonance imaging for acute ischemic stroke. *Biomed Pap Med Fac Univ Palacky Olomouc Czech Repub.* 2009;153:181–187.
- Wintermark M, Reichhart M, Thiran JP, Maeder P, Chalaron M, Schnyder P, Bogousslavsky J, Meuli R. Prognostic accuracy of cerebral blood flow measurement by perfusion computed tomography, at the time of emergency room admission, in acute stroke patients. *Ann Neurol.* 2002;51:417–432.
- Weber R, Ramos-Cabrer P, Hoehn M. Present status of magnetic resonance imaging and spectroscopy in animal stroke models. *J Cereb Blood Flow Metab.* 2006;26:591–604.
- Kidwell CS, Saver JL, Mattiello J, Starkman S, Vinuela F, Duckwiler G, Gobin YP, Jahan R, Vespa P, Kalafut M, Alger JR. Thrombolytic reversal of acute human cerebral ischemic injury shown by diffusion/perfusion magnetic resonance imaging. *Ann Neurol.* 2000;47:462–469.
- Mlynash M, Olivot JM, Tong DC, Lansberg MG, Eyngorn I, Kemp S, Moseley ME, Albers GW. Yield of combined perfusion and diffusion MR imaging in hemispheric TIA. *Neurology.* 2009;72:1127–1133.
- Sicard KM, Henninger N, Fisher M, Duong TQ, Ferris CF. Differential recovery of multimodal MRI and behavior after transient focal cerebral ischemia in rats. *J Cereb Blood Flow Metab.* 2006;26:1451–1462.
- Clark JB. N-acetyl aspartate: a marker for neuronal loss or mitochondrial dysfunction. *Dev Neurosci.* 1998;20:271–276.
- Pereira AC, Saunders DE, Doyle VL, Bland JM, Howe FA, Griffiths JR, Brown MM. Measurement of initial N-acetyl aspartate concentration by magnetic resonance spectroscopy and initial infarct volume by MRI predicts outcome in patients with middle cerebral artery territory infarction. *Stroke.* 1999;30:1577–1582.
- Federico F, Simone IL, Lucivero V, Giannini P, Laddomada G, Mezzapesa DM, Tortorella C. Prognostic value of proton magnetic resonance spectroscopy in ischemic stroke. *Arch Neurol.* 1998;55:489–494.
- Friedman SD, Brooks WM, Jung RE, Hart BL, Yeo RA. Proton MR spectroscopic findings correspond to neuropsychological function in traumatic brain injury. *AJNR Am J Neuroradiol.* 1998;19:1879–1885.
- Garnett MR, Blamire AM, Corkill RG, Cadoux-Hudson TA, Rajagopalan B, Styles P. Early proton magnetic resonance spectroscopy in normal-appearing brain correlates with outcome in patients following traumatic brain injury. *Brain.* 2000;123:2046–2054.
- Lei H, Berthet C, Hirt L, Gruetter R. Evolution of the neurochemical profile after transient focal cerebral ischemia in the mouse brain. *J Cereb Blood Flow Metab.* 2009;29:811–819.
- Hirt L, Badaut J, Thevenet J, Granziera C, Regli L, Maurer F, Bonny C, Bogousslavsky J. D-JNK11, a cell-penetrating c-Jun-N-terminal kinase inhibitor, protects against cell death in severe cerebral ischemia. *Stroke.* 2004;35:1738–1743.
- Hennig J. Multiecho imaging sequences with low refocusing flip angles. *J Magn Reson.* 1988;78:397–407.
- Kunz N, van de Looij Y, Huppi PS, Sizonenko SV, Gruetter R. Feasibility of in-vivo diffusion tensor echo planar imaging and fiber tracking at 14.1T. *Proc Intl Soc Mag Reson Med.* 2009; p 1378.
- van der Zwaag W, Marques JP, Lei H, Just N, Kober T, Gruetter R. Minimization of Nyquist ghosting for echo-planar imaging at ultra-high fields based on a 'negative readout gradient' strategy. *J Magn Reson Imaging.* 2009;30:1171–1178.
- Gruetter R, Tkac I. Field mapping without reference scan using asymmetric echo-planar techniques. *Magn Reson Med.* 2000;43:319–323.
- Mlynarik V, Gambarota G, Frenkel H, Gruetter R. Localized short-echo-time proton MR spectroscopy with full signal-intensity acquisition. *Magn Reson Med.* 2006;56:965–970.
- Tkac I, Starcuk Z, Choi IY, Gruetter R. In vivo ¹H NMR spectroscopy of rat brain at 1 ms echo time. *Magn Reson Med.* 1999;41:649–656.
- Provencher SW. Estimation of metabolite concentrations from localized in vivo proton NMR spectra. *Magn Reson Med.* 1993;30:672–679.
- Easton JD, Saver JL, Albers GW, Alberts MJ, Chaturvedi S, Feldmann E, Hatsukami TS, Higashida RT, Johnston SC, Kidwell CS, Lutsep HL, Miller E, Sacco RL. Definition and evaluation of transient ischemic attack: a scientific statement for healthcare professionals from the American Heart Association/American Stroke Association Stroke Council; Council on Cardiovascular Surgery and Anesthesia; Council on Cardiovascular Radiology and Intervention; Council on Cardiovascular Nursing; and the Interdisciplinary Council on Peripheral Vascular Disease. The American Academy of Neurology affirms the value of this statement as an educational tool for neurologists. *Stroke.* 2009;40:2276–2293.
- Neumann-Haefelin T, Kastrup A, de CA, Yenari MA, Ringer T, Sun GH, Moseley ME. Serial MRI after transient focal cerebral ischemia in rats: dynamics of tissue injury, blood-brain barrier damage, and edema formation. *Stroke.* 2000;31:1965–1972.
- Cvoro V, Wardlaw JM, Marshall I, Armitage PA, Rivers CS, Bastin ME, Carpenter TK, Wartolowska K, Farrall AJ, Dennis MS. Associations between diffusion and perfusion parameters, N-acetyl aspartate, and lactate in acute ischemic stroke. *Stroke.* 2009;40:767–772.
- Sager TN, Hansen AJ, Laursen H. Correlation between N-acetylaspartate levels and histopathologic changes in cortical infarcts of mice after middle cerebral artery occlusion. *J Cereb Blood Flow Metab.* 2000;20:780–788.
- Brouns R, Sheorajpanday R, Wauters A, De Surgeloose D, Marien P, De Deyn PP. Evaluation of lactate as a marker of metabolic stress and cause of secondary damage in acute ischemic stroke or TIA. *Clin Chim Acta.* 2008;397:27–31.
- Frykholm P, Hillered L, Langstrom B, Persson L, Valtysson J, Enblad P. Relationship between cerebral blood flow and oxygen metabolism, and extracellular glucose and lactate concentrations during middle cerebral

- artery occlusion and reperfusion: a microdialysis and positron emission tomography study in nonhuman primates. *J Neurosurg.* 2005;102:1076–1084.
27. Bisschops RH, Kappelle LJ, Mali WP, van der Grond J. Hemodynamic and metabolic changes in transient ischemic attack patients: a magnetic resonance angiography and (1)H-magnetic resonance spectroscopy study performed within 3 days of onset of a transient ischemic attack. *Stroke.* 2002;33:110–115.
 28. Giroud M, Walker P, Guy F, Lemesle M, Lalonde A, Baudouin N, Martin D, Couveur G, Brunotte F. Cerebral metabolism after transient ischemic attack. A 1H MR spectroscopy study. *Neurol Res.* 1999;21:563–565.
 29. Higuchi T, Fernandez EJ, Maudsley AA, Shimizu H, Weiner MW, Weinstein PR. Mapping of lactate and N-acetyl-L-aspartate predicts infarction during acute focal ischemia: in vivo 1H magnetic resonance spectroscopy in rats. *Neurosurgery.* 1996;38:121–129.
 30. Saransaari P, Oja SS. Modulation of taurine release in ischemia by glutamate receptors in mouse brain stem slices. *Amino Acids.* 2010;38:739–746.
 31. Hertz L. Bioenergetics of cerebral ischemia: a cellular perspective. *Neuropharmacology.* 2008;55:289–309.
 32. Nagelhus EA, Lehmann A, Ottersen OP. Neuronal–glial exchange of taurine during hypo-osmotic stress: a combined immunocytochemical and biochemical analysis in rat cerebellar cortex. *Neuroscience.* 1993;54:615–631.
 33. Decavel C, Hatton GI. Taurine immunoreactivity in the rat supraoptic nucleus: prominent localization in glial cells. *J Comp Neurol.* 1995;354:13–26.
 34. Liebeskind DS. Imaging the future of stroke: I. Ischemia. *Ann Neurol.* 2009;66:574–590.
 35. Saenger AK, Christenson RH. Stroke biomarkers: progress and challenges for diagnosis, prognosis, differentiation, and treatment. *Clin Chem.* 2010;56:21–33.
 36. Mekte R, Mlynarik V, Gambarota G, Hergt M, Krueger G, Gruetter R. MR spectroscopy of the human brain with enhanced signal intensity at ultrashort echo times on a clinical platform at 3T and 7T. *Magn Reson Med.* 2009;61:1279–1285.



Stroke

JOURNAL OF THE AMERICAN HEART ASSOCIATION

FINAL PROOF