

Clinical Research

Distinct Behavioral and EEG Topographic Correlates of Loss of Consciousness in Absences

*†P. Vuilleumier, *F. Assal, *O. Blanke, and *P. Jallon

*Department of Neurology, EEG and Clinical Epileptology Unit, and Brain Mapping Laboratory, University Hospital of Geneva, Switzerland; and †Department of Neurology, VANCHCS and University of California at Davis, Davis, California, U.S.A.

Summary: *Purpose:* To describe the behavioral and EEG topographic correlates of absences with 3-Hz generalized spike-waves and partitioned impairment of consciousness.

Methods: Two adult women had so-called “phantom” absences, characterized by brief and mild impairments of consciousness that were previously inconspicuous to both patient and physician. Neuropsychological examination was performed under video-EEG monitoring during absence status. EEG topographic mapping of spike-wave discharges was obtained in the two cases.

Results: Only mild attentional and executive disturbances were observed during absence status despite prolonged discharges. Spike-wave bursts were associated with selective impairment in the initiation of response and self-generated action, whereas short-term storage of external information during discharges was fully preserved. This is consistent with a predomi-

nant involvement of frontomesial cortex demonstrated by topographic mapping of spike-wave discharges in the two cases. By contrast, in two other patients with typical absences and a complete lack of retention for information given during the discharges, topographic mapping found a more lateral frontal involvement by spike-wave activity.

Conclusions: Different types of absence seizures may impair distinct components of conscious behavior. A predominant involvement of frontomesial thalamocortical circuitry may underlie an “inconspicuous” disorder of consciousness as seen in phantom absences with selective loss of initiation and goal-oriented behavior, whereas involvement of more lateral frontal areas in typical absences may additionally disrupt working memory processes. **Key Words:** Absence seizure—Absence status—Consciousness—Cingulate cortex—Frontal lobe.

Absence seizures are defined by impairment of consciousness concomitant with 3-Hz generalized spike-wave on EEG (1,2). But absences do not constitute a single disorder, and consciousness is not subserved by a unitary process. Absences occur in several idiopathic epileptic syndromes during childhood or adolescence (1,2) and may occasionally persist into adulthood (3). Absence status also may occur in adults because of drug exposure or withdrawal, or as de novo status (3–5). One form recently emphasized under the term of “phantom absences” is characterized by “brief and mild impairments of consciousness that are inconspicuous to both the patient and physician and may exist for many years before diagnosis” (6,7). It remains unclear whether these cases correspond to a distinct entity (5,7) or a seizure type along a broader continuum of idiopathic epilepsies

(8,9). Variable impairment of consciousness during absences (10,11) or subtle cognitive changes related to interictal spikes known as “transient cognitive impairment” (12) have been long noted. As consciousness cannot be regarded as a unitary phenomenon (13,14), we studied ictal behavior in two cases with so-called phantom absences to learn whether a distinct deficit in the mechanisms of consciousness rather than a different “degree” of deficit may underlie this type of absence. What is actually lost during an inconspicuous loss of consciousness? We also asked whether this deficit would correspond to distinct topographic EEG abnormalities. This may in turn provide valuable insight into the neurologic ingredients of normal conscious behavior.

CASE REPORTS

Patient 1

Patient 1 was a 66-year-old right-handed woman admitted after a generalized tonic-clonic seizure. She had a

Accepted January 19, 2000.

Address correspondence and reprint requests to Dr. P. Vuilleumier at Institute of Cognitive Neuroscience, Alexandra House, 17 Queen Square, London, U.K. E-mail: p.vuilleumier@ucl.ac.uk

first seizure at age 32 after her first child delivery and then only occasional (<1/year) tonic-clonic seizures with valproate (VPA), 900 mg daily. Other seizure types or brief lapses of consciousness were not acknowledged by the patient or relatives. Family history was unremarkable. After admission the patient appeared unusually apathetic and distractible. Neurologic examination was normal. EEG revealed subcontinuous discharges of generalized, bilaterally synchronous spike-wave and polyspike-wave complexes at 3–4 Hz that predominated in the anterior and midline regions (Fig. 1A). Standard assessment performed according to reported techniques (1,2) could not detect typical absences during the discharges (duration, 3–10 s; 16.5% of total recording time), and the patient was totally unaware of them. Neuropsychological testing was carried out under continuous video-EEG monitoring as described later. Spike-wave activity resolved after i.v. clonazepam (CZP), 0.5 mg, and then VPA, 1,500 mg daily. Video-EEGs were normal on the next days except for brief spike-wave bursts during hyperventilation. Brain magnetic resonance imaging (MRI) and HMPAO-Tc99 SPECT during status were unremarkable. Neuropsychological assessment was normal interictally (3 days after status).

Patient 2

Patient 2 was a 58-year-old right-handed woman admitted after a fall, presumably due to a seizure. She had three tonic-clonic generalized seizures between ages 23 and 30, each after child delivery, but no recurrence since then. Treatment with phenytoin (PHT) and phenobarbital (PB) was discontinued 2 years before admission. Other seizure types were not reported, although occasional distractibility with eye closure was admitted by relatives on specific questioning. Family history was unremarkable. Neurologic examination was normal except for slow mentation and unconcern. EEG revealed subcontinuous discharges of generalized, bilaterally synchronous, rhythmic and regular spike-waves and polyspike-waves at 3 Hz that predominated in the frontal and anterior temporal regions (Fig. 1B). Standard assessment could not detect typical absences during the discharges (duration, 2–15 s; 21.3% of total recording time), and the patient was unaware of them. Neuropsychological testing was carried out under continuous video-EEG (see later). EEG abnormalities resolved with CZP, i.v., and then VPA, 1,000 mg t.i.d. Video-EEG on the next day showed normal activity without change during hyperventilation. Brain CT was normal. Neuropsychological assessment performed a few days after status was normal.

Two other patients who had typical absences with complete loss of consciousness during spike-wave bursts and were examined during the same period served as control cases. These were a 15-year-old girl (Fig. 2A)

and a 10-year-old girl (Fig. 2B) in whom EEG showed typical discharges of generalized, bilaterally synchronous 3-Hz spike-wave (duration, 2–20 s). Neither had tonic-clonic seizures. Family history, brain MRI, neurologic, and cognitive functioning were unremarkable in both cases.

METHODS

Behavioral testing was performed in each case under continuous video and EEG monitoring according to reported techniques (1), including responsiveness to (auditory, visual, or tactile) stimulation, continuous tapping, holding arms outstretched, sitting or standing, breath counting, reciting of automatic series or prose passages, as well as a detailed standardized neuropsychological examination (see later). Topographic mapping of the spike-wave activity was performed by using a quantitative method that allows definition of the generator of epileptic discharges in frequency and spatial coordinates. The method allows the localization of distributed sources and was described in more detail elsewhere (15,16). Twenty electrodes were placed according to the 10–20 international system. The strength of the potential map for every frequency point (0.5–32 Hz) was calculated for the period of the spike-wave bursts with a resolution of 0.5 Hz over all electrodes (16). Subsequently, a linear inverse solution was applied by using low-resolution electromagnetic tomography (LORETA) (15) to define the generator of the epileptic discharges in three-dimensional spatial coordinates.

RESULTS

Behavioral findings

Despite subcontinuous spike-wave activity on EEG, both patients 1 and 2 were alert and normally oriented. Both were totally unaware of the seizures. Absences were not overtly apparent, but eye blinking and brief up-gaze were frequent during spike-wave in patient 2. Continuous automatic activities such as tapping or counting appeared remarkably maintained, or only briefly suspended or slowed. When asked to count their breaths aloud during hyperventilation while maintaining the arms outstretched, the patients made only a few occasional pauses or hesitations during paroxysms, and then immediately resumed counting (Fig. 1A). However, these pauses were more frequent when counting backward than forward and disclosed only by careful video-EEG observation. Most notably, video-EEG revealed brief but consistent interruptions in new or goal-oriented gestures, or latency in answers to questions given during a discharge. However, a most prominent feature in both patients was that questions, commands, or complex sentences given during a discharge were strikingly well re-

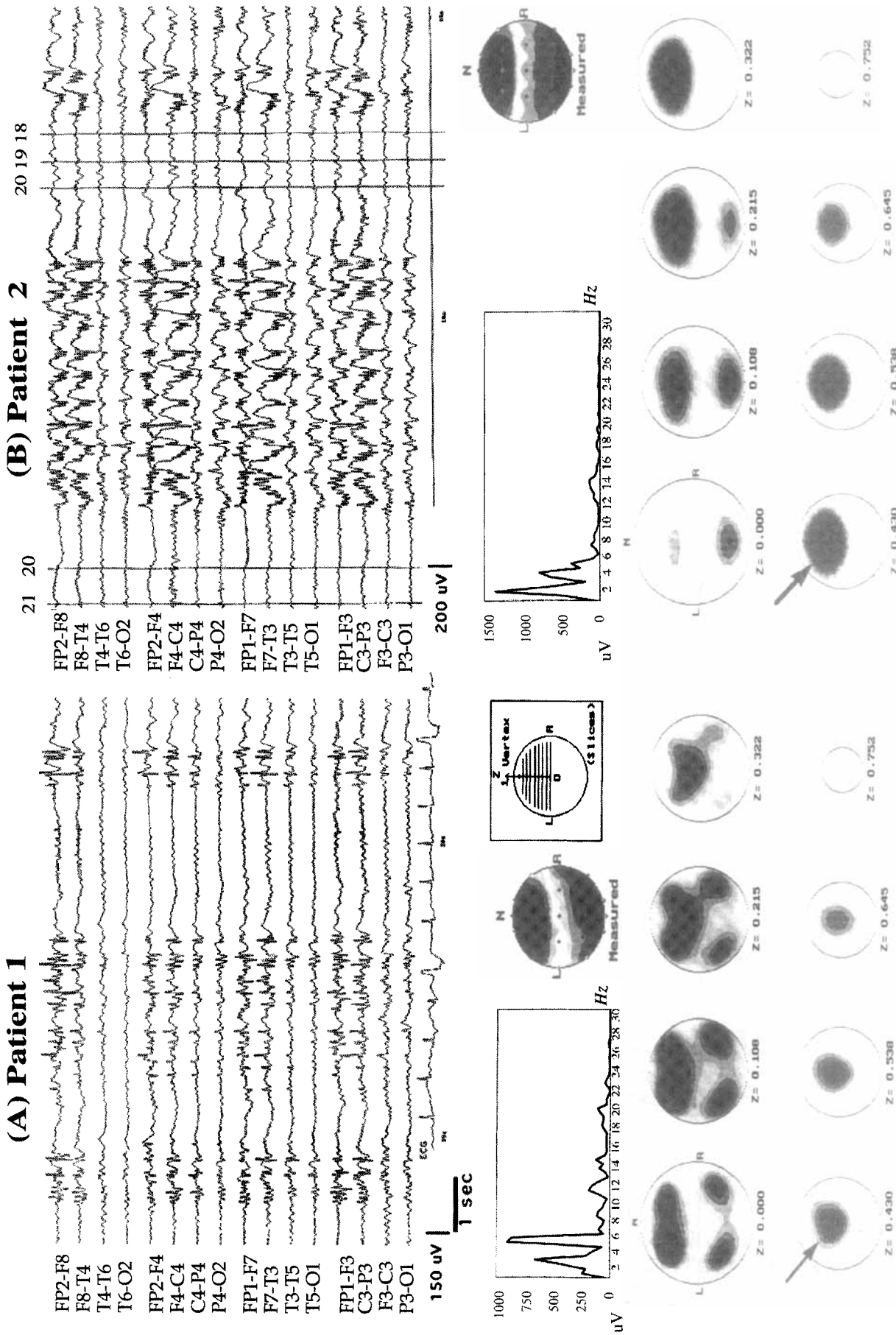
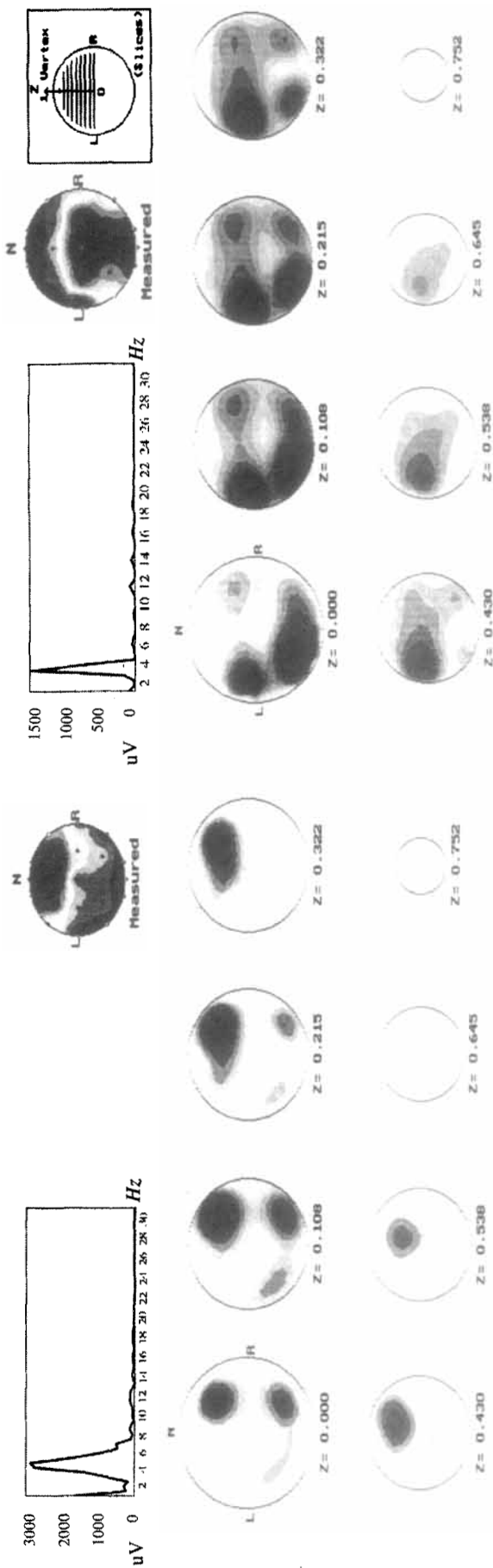
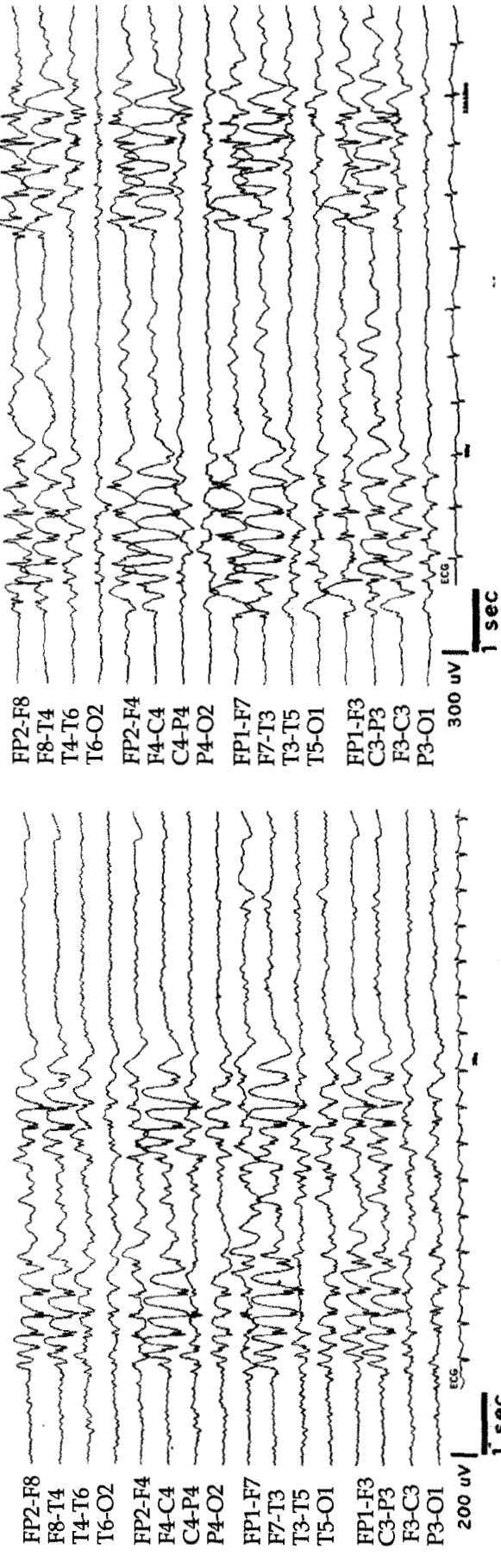


FIG. 1. Top: EEG; from patient 1 (A) and patient 2 (B), showing fragmented bursts of generalized, bilaterally synchronous rhythmic spike-wave and polyspike-wave complexes, predominant in both frontal regions. Hyperventilation increased discharges in patient 1, but intermittent photic stimulations were without effect in both cases. There was no evidence of secondary bilateral synchrony. Note that patient 2 stopped counting backward (as denoted by the numbers 22 to 18) during the discharge and spontaneously resumed counting after the latter ended. **Middle:** Power spectra from frequency analysis of a 2-s period of spike-waves, showing two main peaks between 3 and 6 Hz in patient 1 (A) and between 2 and 4 Hz in patient 2 (B). **Bottom:** Three-dimensional spatial localization of spike-waves activity by low-resolution electromagnetic tomography (LORETA) based on the dominant frequencies in each case (6 and 2 Hz in patients 1 and 2, respectively), showing prominent involvement of the upper midline frontal areas (slices $z = 0.108-0.645$) in both patients (arrows). Weaker bilateral temporal involvement also was present in patient 1. LORETA mapping based on the other dominant frequencies (3 and 4 Hz in patients 1 and 2, respectively) showed the same spatial distribution in each case.

(A) Control 1



(B) Control 2

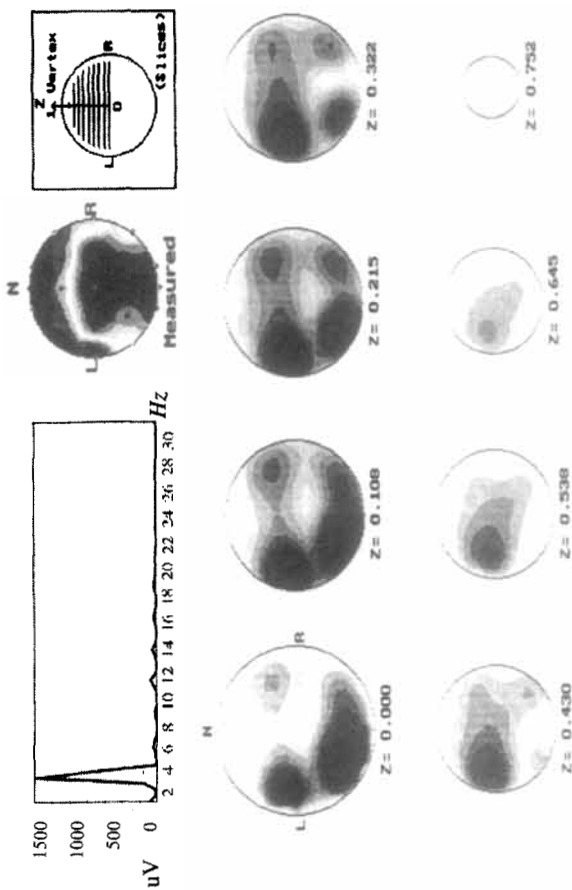



FIG. 2. Top: EEG, from two control patients with typical absences showing short discharges of generalized, bilaterally synchronous 3-Hz spike and waves. Middle: Power spectra from frequency analysis of a 2-s period of spike-waves showing a single peak at 3 Hz in both control patients. Bottom: Spatial localization of spike-waves by low-resolution electromagnetic tomography (LORETA) based on the dominant frequencies in each case. There is no similar involvement of the upper midline frontal areas (slices $z \geq 0.538$) compared with patients 1 and 2, and much greater involvement of the lateral frontal and posterior cortical areas at a lower level (slices $z = 0.00-0.43$), with marked right-sided predominance in control 1 (A) and slight left-sided predominance in control 2 (B).

tained, although they could be repeated or responded to postictally only (always with accuracy). These retention abilities were exceedingly sensitive to interference; confusion or mix-up occurred as soon as any other word was inadvertently uttered by someone in the room other than the examiner, or when the material to be retained was presented with other irrelevant information (e.g., some incentive phrase). When given with a task to do or a calculation to perform, the order was usually repeated at the end of the discharge and then executed. Initiation of deliberate responses or purposeful actions was never observed during a paxoxysm. Patient 2 sometimes carried on simple or automatic motor activities (e.g., rubbing her face or hand) but never initiated a new goal-directed behavior during a discharge.

Neuropsychological testing showed normal language, writing, arithmetics, praxis, visual recognition, and learning abilities. Verbal and visuospatial short-term memory were normal, as assessed by digit span and Corsi blocks span, even though spike-wave paroxysms could occur during the tasks. In patient 2, long-duration discharges allowed digit span to be measured during them, and it was found to be of five (i.e., strings up to five digits long provided to the patient during sustained spike-wave bursts could be correctly reproduced after the bursts' end). Frontal executive functions were unimpaired on Luria's alternating tasks and mental control subtests from the WAIS, but sustained attention capabilities on a continuous performance task were impaired. Both patients succeeded in counting backward and serial threes subtraction; patient 2 failed serial sevens. Controlled oral fluency was in the normal range in patient 1 but slightly impaired in patient 2 (irrespective of intervening discharges). Again, video-EEG analysis noted that the initiation of deliberate responses was selectively abolished or delayed in several tasks during spike-wave paxoxysms, whereas the ability to retain questions or commands and eventually to perform the task afterward seemed unaffected.

By contrast, the two control cases with typical absences consistently showed complete loss of consciousness and no registration at all of any information and stimuli presented during their absences. Neuropsychological testing between bursts was normal, including oral and written language, drawing, arithmetics, frontal executive functions (Luria's tasks, backward counting), and verbal and visual learning memory. All motor and cognitive activities were interrupted by discharges except for variable maintaining of simple limb postures (outstretched arms). Any command provided during spike-wave bursts was never executed afterward nor recalled. Verbal digit span and visuospatial blocks span were normal between bursts but always failed when spike-wave paroxysms occurred during the task (even single items).

EEG mapping

In patient 1, quantitative frequential analysis of spike-wave bursts revealed three dominant frequency peaks at 5.5, 3.0, and 11 Hz, in decreasing order of importance, respectively (Fig. 1A). The LORETA algorithm localized the generator of all three frequencies in the medial frontal areas bilaterally, as well as in both temporal areas. In patient 2, frequency analysis revealed three dominant peaks at 2.0, 4.0, and at 13 Hz; LORETA showed that all three frequencies were localized bilaterally in medial areas of the frontal lobes (Fig. 1B). In both cases, LORETA mapping was very consistent and similar across frequencies and bursts.

Clearly different patterns were obtained in the two patients, with typical absences and complete loss of consciousness during bursts. A single dominant frequency (2–3 Hz) was found for the spike-wave pattern without other peaks in the alpha or beta range (Fig. 2). The LORETA algorithm localized spike-wave generators predominantly in the lower lateral frontal and temporal areas, more so on the right side in control 1 and slightly more on the left side in control 2. In both cases, LORETA maps appeared slightly more variable across bursts than in the two previous patients. However, there was no consistent involvement of frontal midline areas in upper slices.

DISCUSSION

Our two patients had a similar history of infrequent tonic-clonic seizures and absence status with 3-Hz spike-wave first diagnosed in late childhood. Absences had not been detected previously. These cases cannot be classified with confidence into one of the recognized idiopathic syndromes (2,3). They fit the clinical description of phantom absences recently defined by Panayiotopoulos et al. (6,7), although it remains questionable whether these correspond to a specific syndrome (7) or just a seizure type that may belong to different age-related syndromes (9). Of particular interest in our two patients, close behavioral examination and video-EEG monitoring were required to disclose transient and specific alterations of consciousness during prolonged discharges. These were characterized by subtle but consistent deficits in initiating actions or responses, and the patients, relatives, or even medical staff were totally unaware of absences despite prolonged spike-wave activity.

Absences are not a uniform symptom but have different clinical and EEG manifestations, which may be syndrome related (1–3). Disturbance of consciousness during spike-wave bursts is always severe in childhood absence epilepsy, with complete interruption of all mental activities and no retention of ictal events (1), whereas it is often mild in juvenile myoclonic epilepsy (17). In the

latter, expressive speech is variably interrupted, but receptive speech can be preserved with partial recollection of ictal events as in our two cases. In absence status, the manifestations may range from minimal behavioral changes to prolonged confusional states (5,10,18). Neuropsychological testing performed ictally in a few cases showed that failure of sustained attention, lack of initiative, paucity of speech, defect in planning, perseveration, and memory disturbances are predominant (10, 18–20). These cases may be difficult to distinguish from partial complex nonconvulsive status epilepticus of frontal origin (19,21).

Detailed assessment in our two patients revealed only mild attentional and executive disturbances during their subcontinuous absence status. Prolonged spike-wave bursts caused a selective impairment in the initiation of goal-directed behavior and response selection, whereas the ability to carry out automatic activities or to retain external information such as complex sentences, commands, or calculations was remarkably preserved. Tasks ordered during a discharge could be executed only after the latter ceased and the patient self-repeated the order. Digit span was normal even during long-duration spike-wave bursts. This suggests that complex linguistic functions and upholding processes in short-term (working) memory were basically intact. This contrasts with other transient cognitive impairments associated with spike-wave bursts that predominantly affect working memory function (12,22). In our patients, ictal discharges rather disrupted processes that contribute to initiation of response and self-generated behavior.

Intention and response initiation processes are central in the multifaceted construct of consciousness (13,23). They are generally considered to involve an executive attentional system subserved by the anterior cingulate and adjacent cortex of the medial frontal lobes (13,14, 24,25), whereas information-holding processes of working memory involve dorsolateral frontal and more posterior cortical areas (26). Bilateral dysfunction of medial prefrontal regions typically results in akinetic mutism. Remarkably, LORETA mapping of spike-wave bursts in our two patients revealed maximal ictal activity in medial frontal regions. This was unlike the two control cases, who had typical absences with complete loss of consciousness and no retention of information during EEG paroxysms. Several topographic EEG mapping studies found prominent implication of frontomesial cortical areas in absence seizures (27–30). However, these studies often involved adult patients with potentially atypical absences. A recent study using functional MRI triggered by EEG paroxysms also reported activation of the anterior cingulate cortex during seizures in a patient with absence epilepsy (31), but no behavioral or neuropsychological information was provided. Preferential involvement of frontomesial cortex by spike-wave parox-

ysms generated within the thalamocortical circuitry in some absence seizures (30) could disrupt those aspects of conscious behavior related to intention and response initiation without disrupting the ability to retain information in short-term memory. This feature might underlie the inconspicuous impairment of consciousness in so-called phantom and other “mild” absences. Conversely, in cases with typical absences, additional involvement of the lateral frontal or posterior cortical areas by more generalized spike-waves may explain impairment of short-term memory processes during discharges (12,22).

We have no straightforward explanation for the asymmetry of spike-wave generators found in the cases with typical absences (control 1), but this could result from differences in burst amplitudes. Spatial sources appeared slightly more variable across bursts in the two controls than in the two other patients. LORETA has limited spatial resolution but appears reliable for the location of lateralized focal seizures and particularly suitable for distributed sources (unlike dipole source models) (15,16). Spike-wave asymmetries are not uncommon on the EEG in typical absence seizures (see Fig. 2) and may influence the spatial extent of sources in topographic mapping, although this should not affect the distinction between medial and lateral cortical generators that we found in frontal regions.

Further studies should investigate whether such asymmetries in the involvement of lateral cortical areas correspond to a differential verbal versus visuospatial deficit in short-term memory during absences (22,32), unnoticed in our present testing procedure. EEG in our two patients also differed from the controls in that it showed more polyspikes and fewer prominent slow waves, as reflected by the frequency analysis of paroxysms. Such a pattern is not uncommon in atypical absences (3,7). Importantly, a similar topographic EEG mapping was obtained for all three frequency peaks in the patients. Although it is possible that succeeding slow waves may be more disruptive to cognitive functioning than spikes themselves (32), we believe that this cannot account by itself for a selective impairment in intention-based conscious behavior with a relative sparing of other reception-based aspects in our two patients. Alternatively, one would have to speculate that intentional response-initiation processes are more sensitive to higher frequency discharges than are other cognitive operations. Our findings therefore suggest that different types of absence seizures might impair distinct components in the complex processes subserving consciousness, and that topographic differences in discharges might account for the distinct behavioral expression.

Acknowledgment: We thank Christophe Michel for his help in the use of the LORETA mapping technique, Albert Nahory for technical assistance during EEG recordings, and Fabienne Picard for helpful comments.

REFERENCES

1. Panayiotopoulos CP, Obeid T, Waheed G. Differentiation of typical absence seizures in epileptic syndromes: a video-EEG study of 224 seizures in 20 patients. *Brain* 1989;112:1039-56.
2. Porter RJ. The absence epilepsies. *Epilepsia* 1993;34(suppl 3):42-8.
3. Panayiotopoulos CP, Chroni E, Daskalopoulos C, Baker A, Rowlinson S, Walsh P. Typical absence seizures in adults: clinical, EEG, video-EEG findings and diagnostic/syndromic considerations. *J Neurol Neurosurg Psychiatry* 1992;55:1002-8.
4. Thomas P, Beaumanoir A, Genton P, Dolisi C, Chatel M. "De novo" absence status of late onset: report of 11 cases. *Neurology* 1992;42:104-10.
5. Lee SI. Nonconvulsive status epilepticus. *Arch Neurol* 1985;42:778-81.
6. Ferner RE, Panayiotopoulos CP. "Phantom" typical absences, absence status and experiential phenomena. *Seizure* 1993;2:253-6.
7. Panayiotopoulos CP, Koutroumanidis M, Giannakodimos S, Agathonikou A. Idiopathic generalised epilepsy in adults manifested by phantom absences, generalised tonic-clonic seizures, and frequent absence status. *J Neurol Neurosurg Psychiatry* 1997;63:622-7.
8. Berkovic SF, Andermann F, Andermann E, Gloor P. Concepts of absence epilepsies: discrete syndromes or biological continuum? *Neurology* 1987;37:993-1000.
9. Tiacchi C, D'Alessandro P, Cantisani TA, Bartocci A, Ibba A, Ferroni A. So-called "petit mal status": epileptic syndrome or seizure type? *Ital J Neurol Sci* 1995;16:279-94.
10. Andermann F, Robb JP. Absence status. *Epilepsia* 1972;13:177-87.
11. Boudin G, Barbizet J, Masson S. Etude de la dissolution de la conscience dans 3 cas de petit mal avec crises prolongées. *Rev Neurol* 1958;99:483-7.
12. Aarts JHP, Binnie CD, Smit AM, Wilkins AJ. Selective cognitive impairment during focal and generalized epileptiform EEG activity. *Brain* 1984;107:293-308.
13. Posner MI, Rothbart MK. Attentional mechanisms and conscious experience. In: Milner AD, Rugg MD, eds. *The neuropsychology of consciousness*. London: Academic Press, 1991:90-111.
14. Ingvar DH. The will of the brain: cerebral correlates of willful acts. *J Theor Biol* 1994;171:7-12.
15. Pascual-Marqui RD, Michel C, Lehman D. Low resolution electromagnetic tomography: a new method for localizing electrical activity in the brain. *Int J Psychophysiol* 1994;18:49-64.
16. Lehmann D, Michel CM. Intracerebral dipole source localization for FFT power maps. *Electroencephalogr Clin Neurophysiol* 1990;76:271-6.
17. Panayiotopoulos CP, Obeid T, Waheed G. Absences in juvenile myoclonic epilepsy: a clinical and video-electroencephalographic study. *Ann Neurol* 1989;25:391-7.
18. Nightingale S, Welch JL. Psychometric assessment in absence status. *Arch Neurol* 1982;39:516-9.
19. Guberman A, Cantu-Reyna G, Stuss D, Broughton R. Nonconvulsive generalized status epilepticus: clinical features, neuropsychological testing, and long-term follow-up. *Neurology* 1986;36:1284-91.
20. Geier S. Prolonged psychic epileptic seizures: a study of absence status. *Epilepsia* 1978;19:431-45.
21. Vuilleumier P, Despland PA, Regli F. Failure to recall (but not to remember): pure transient amnesia during nonconvulsive status epilepticus. *Neurology* 1996;46:1036-9.
22. Hutt SJ, Gilbert S. Effects of evoked spike-wave discharges upon short term memory in patients with epilepsy. *Cortex* 1980;16:445-57.
23. James W. *Principles of psychology*. New York: Holt, 1890.
24. Frith CD, Friston K, Liddle PF, Frackowiak RSJ. Willed action and the prefrontal cortex in man: a study with PET. *Proc R Soc Lond (Biol)* 1991;244:241-6.
25. Devinsky O, Morrel MJ, Vogt BA. Contributions of the anterior cingulate cortex to behaviour. *Brain* 1995;118:279-306.
26. Smith EE, Jonides J. Working memory in humans: neuropsychological evidence. In: Gazzaniga MS, ed. *The cognitive neurosciences*. Cambridge: MIT Press, 1995:1009-20.
27. Rodin E, Ancheta O. Cerebral electric fields during petit mal absences. *Electroencephalogr Clin Neurophysiol* 1987;66:457-66.
28. Rodin EA, Rodin MK, Thompson JA. Source analysis of generalized spike-wave complexes. *Brain Topogr* 1994;7:113-9.
29. Ferri R, Illiceto G, Carlucci V. Topographic EEG mapping of 3/s spike-and-wave complexes during absence seizures. *Ital J Neurol Sci* 1995;16:541-7.
30. Niedermeyer E. Primary (idiopathic) epilepsy and underlying mechanisms. *Clin Electroencephalogr* 1996;27:1-21.
31. Warach S, Ives JR, Schlaug G, et al. EEG-triggered echo-planar functional MRI in epilepsy. *Neurology* 1996;47:89-93.
32. Shewmon DA, Erwin RJ. Focal spike-induced cerebral dysfunction is related to after-coming slow-wave. *Ann Neurol* 1988;23:131-7.