

Functional MRI With Simultaneous EEG Recording: Feasibility and Application to Motor and Visual Activation

François Lazeyras, PhD,^{1*} Ivan Zimine, BSc,^{1,2} Olaf Blanke, MD,³ Stephen H. Perrig, MD,³ and Margitta Seeck, MD³

The possibility of combining the high spatial resolution of functional magnetic resonance imaging (fMRI) with the high temporal resolution of electroencephalography (EEG) may provide a new tool in cognitive neurophysiology, as well as in clinical applications such as epilepsy. However, the simultaneous recording of EEG and fMRI raises important practical problems: 1) the patients' safety, in particular the risk of skin burns due to electrodes heating; 2) the impairment of the EEG recording by the static magnetic field, as well as by RF and magnetic field gradients used during MRI; and 3) the quality of MR images, which may be affected by the presence of conductors and electronic devices in the MRI bore. Here we present our experiences on 19 normal volunteers who underwent combined fMRI and 16-channel EEG examination. Consistent with previous reports, safety could be assured when performing EEG recordings during fMRI acquisition. Electrophysiological signals recorded with surface EEG were similar inside and outside the 1.5 T magnet. Furthermore, fMRI using motor or visual tasks revealed similar areas of activation when performed with and without 16-channel EEG recording. *J. Magn. Reson. Imaging* 2001; 13:943–948. © 2001 Wiley-Liss, Inc.

Index terms: functional MRI; EEG; artifact; temperature; safety

THE POSSIBILITY TO RECORD multichannel electroencephalogram (EEG) in the magnet (1) may offer new insights in the investigation of brain functions. The combination of two techniques, EEG and functional magnetic resonance imaging (fMRI), may yield a new neuroimaging tool that combines the excellent temporal

resolution of the EEG with the good spatial resolution of fMRI (2). Such a tool could be used in both cognitive neuroscience and clinical neurology, such as epilepsy (3). Several studies have successfully applied EEG-triggered fMRI to visualize brain regions related to the generation of epileptogenic spikes (4–6), but little has been done in cognitive neurosciences (7).

Potential problems may appear when concurrent EEG and fMRI acquisition is performed. On the one hand, the presence of electrodes in the image field of view (FOV) may produce MRI artifacts due to susceptibility effect or radiofrequency (RF) interaction with the conductive wires. On the other hand, the EEG recording may be impaired by the presence of the main magnetic field (B_0), as well as by RF and switched gradients used during MRI acquisitions. Although methods have been proposed to restore electrophysiological signals during MR acquisition (8), no attempt has been made to implement this solution in practice—the principal reason being the difficulty to avoid preamplifier saturation of EEG systems due to induced current by switched gradients. Moreover, if fMRI is triggered by EEG-measured signals, good quality EEG recordings between MR acquisitions, rather than during MR scanning, are required. In the latter situation, only B_0 affects the quality of the EEG recording, producing electrocardiogram artifacts (1,9,10). However, it has been shown by different research groups that a good quality EEG recording can be obtained inside a 1.5 T magnet, allowing the detection of epileptic discharges (4–6,11).

Another important concern is the safety of the patient associated with the use of the EEG device during MRI acquisition. This risk is due to induced currents in EEG conductors, which can be caused by the static magnetic field, switching magnetic gradient fields, or RF interaction. A recent theoretical article reviewed the different mechanisms that induce currents in electrical wires used for EEG recording inside the magnet and the associated risks for the patient (12). The authors found that the single most important potential hazard is due to RF interaction, and they concluded that recording an EEG during MRI acquisition is safe if series resistors are added for MRI sequences with maximum specific absorption rate (SAR) values. This represents a serious

¹Department of Radiology, University Hospital of Geneva, Micheli-du-Crest 24, 1211 Geneva, Switzerland.

²Group of Applied Physics, Section of Physics, University of Geneva, Geneva, Switzerland.

³Laboratory of Presurgical Epilepsy Evaluation, Program of Functional Neurology and Neurosurgery, University Hospitals of Lausanne and Geneva, Switzerland.

Contract grant sponsor: Swiss National Science Foundation; Contract grant numbers: 31-52933.97, 32-52991.97, 31-57112.99.

Presented in part at the 6th Annual Meeting of the International Society for Magnetic Resonance in Medicine, Sydney, Australia, 1998.

*Address reprint requests to: F.L., Department of Radiology, University Hospital of Geneva, rue Micheli-du-Crest 24, 1211 Geneva 14, Switzerland. E-mail: francois.lazeyras@hcuge.ch

Received November 21, 2000; Accepted November 21, 2000.

Table 1
Sequence Parameters

Sequence	TR [msec]	TE [msec]	Flip angle [degree]	ETL	Number of slices	NAV	Acquisition time [minute]	SAR ^a [W/kg]
FSE	6430	90	90	32	13	3	3.0	2.6 ± 0.15
SE	344	16	90	1	13	2	3.0	1.0 ± 0.05
GRE	167	4.7	80	1	13	4	3.0	0.7 ± 0.02
EPI	1200	40	90	1	13	140	3.0	0.08 ± 0.01

TR = repetition time, TE = echo time, ETL = echo train length, NAV = number of averages.

^a Mean ± S.D, n = 11.

concern, since added serial resistors will compromise the quality of the EEG recording.

In the present study, we addressed the important question of safety of EEG recordings in the magnet by exploring the technique in 11 healthy volunteers. Our approach was experimental rather than theoretical, and we measured the temperature rise of the electrodes under various MRI acquisition conditions. We also determined the effect of the EEG system on the MRI acquisitions, as well as the effect of the magnet on the EEG recording. In eight other volunteers, we performed motor and visual fMRI in order to compare the area of activation with and without a 16-channel MR-compatible EEG system.

MATERIALS AND METHODS

Subjects

Nineteen normal volunteers underwent a combined EEG-fMRI study after informed consent was given. Eleven volunteers had an MRI examination with fast spin echo (FSE), spin echo (SE), gradient echo (GRE), and echo planar imaging (EPI). All acquisitions were performed with and without the 16 scalp EEG electrodes. On five of these subjects, additional temperature measurements of one electrode were performed. This first series of experiments was designed to address the overall feasibility of the technique, especially the safety issue related to the risk of heating due to RF interaction with the transmit coil, as well as to check the EEG quality inside the magnet.

In order to study the effect of EEG on fMRI activation, we performed fMRI experiments on eight other healthy volunteers, using a simple finger-tapping paradigm on five of them and visual stimulation on the other three.

EEG Recording and Analysis

Sixteen gold-coated silver electrodes (Neuroscan Inc., Sterling, VA) were applied to the skin with conductive paste according to standard positions of the 10/20 system. Data were recorded continuously on a 64-channel EEG machine (Deltamed SA, Paris, France) with a sampling rate of 128 Hz.

Several eyes-open and eyes-closed EEG sequences were recorded from the volunteers in order to check for proper spontaneous EEG, in particular, eye movement artifacts in the frontal leads, as well as the apparition of posterior alpha rhythm initiated when the eyes are closed. No further use of the EEG was made in the volunteers.

MRI

A 1.5 Tesla ECLIPSE system (Marconi Medical Systems, Cleveland, OH), equipped with fast gradients (27 mT/m with a slew rate of 72 mT/m/msec), was used, permitting single-shot EPI. The standard head coil configuration of our system was used, with a receive head coil and a transmit body coil with a maximum RF power output of 25 kW. The SAR of the pulse sequence was provided by the manufacturer according to the automatic RF calibration procedure of our MRI system. The SAR measures the absorption of electromagnetic energy in the body and depends on the subject's body weight and sequence parameters. For the present study, the maximum SAR is reported in W/kg. For cerebral imaging, a first level of warning is given at 1.2 W/kg and the system does not allow any acquisition for a maximum SAR level higher than 2.8 W/kg.

The following sequences have been used and compared with and without the EEG system: FSE, SE, GRE, and EPI. The sequence parameters are listed in Table 1.

The temperature measurements were performed using a type K (Ni-Cr/Ni-Al) thermocouple (Omega Engineering Inc., Stamford, CT) at the end of each acquisition. After proper tip isolation, the thermocouple was placed in the conductive paste under one electrode. Skin measurement without an electrode was also done with the paste kept in place.

fMRI Acquisition and Analysis

Eight normal right-handed volunteers participated in the fMRI study. Each subject had two fMRI acquisitions, one with the EEG electrodes and a second one without the electrodes. fMRI data were obtained from 13–15 contiguous 5-mm slices using single-shot EPI (TR/TE/flip angle = 2 seconds/40 msec/80°). The motor paradigm consisted of four blocks of 20 seconds of rest and 20 seconds of self-paced finger tapping, for a total experiment duration of 2 minutes and 40 seconds. The visual stimulation was designed to activate the visual motion area (MT/V5). The control condition consisted of a 40-second presentation of static vertical lines, and the activation condition was obtained by moving the pattern from right to left for 20 seconds. The control activation block was repeated five times, yielding an experiment duration of 5 minutes. The data analysis was performed off-line using Interactive Data Language (Research Systems, Boulder, CO) on a DEC alpha UNIX station. All studies were first corrected for head motion (13). An intensity threshold of 20% of the

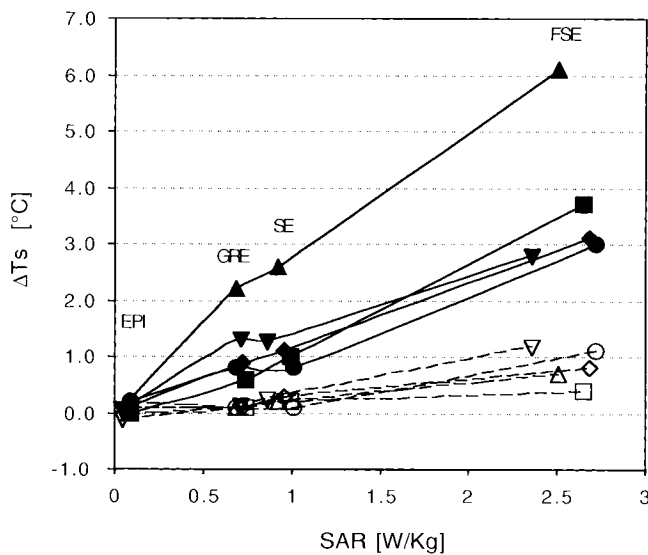


Figure 1. Temperature increase as compared to SAR deposition measured in five volunteers. The graph represents the skin temperature rise following the use of four different sequences (see Materials and Methods) with increasing SAR. The FSE acquisition was adjusted for maximum allowable SAR. The safety limit corresponds to a temperature rise of 8.5° C in these experiments. The open symbols refer to measurements made without electrodes, and the closed symbols refer to measurements made with the EEG system.

maximum image intensity was used to remove the noise. The images corresponding to the two conditions were compared statistically using a cross-correlation computation of each individual pixel with a shifted (4-second) boxcar function as reference (14). Correlation thresholds of 0.45 and 0.35 were used for the motor paradigm and the visual paradigm, respectively. The statistically significant pixels were considered and displayed as a signal percent change from the baseline. Stand-alone pixels were discarded. The signal-to-noise ratio (SNR) of the EPI images (mean signal intensity divided by the mean of the noise of the magnitude im-

age) with and without EEG was compared, as well as the number of activated pixels, the mean cross-correlation coefficient, and the mean signal intensity percent variation.

RESULTS

The FSE sequence was used to evaluate the risk of burning due to RF interaction between the transmit coil and EEG wires, which may produce local heating. No sensation of temperature changes or any kind of discomfort was reported. Figure 1 represents the temperature measurements performed on the five subjects with and without EEG. The initial temperature was $33.1 \pm 0.12^\circ\text{C}$ (mean \pm SD) without the EEG system and $32.9 \pm 0.3^\circ\text{C}$ with the EEG leads connected on the volunteer’s head. For the measurements without electrodes, the largest skin temperature increase (ΔT_s) was observed with the FSE sequence and reached $0.84 \pm 0.32^\circ\text{C}$. No effect was observed with the EPI sequence ($\Delta T_s = 0.06 \pm 0.11^\circ\text{C}$), and the highest temperature rise for GRE and SE was negligible ($\Delta T_s < 0.5^\circ\text{C}$). When the electrodes were attached to the subject’s head, the largest mean temperature increase was observed in the FSE sequence ($\Delta T_s = 3.74 \pm 1.36^\circ\text{C}$), with a peak value on a single subject of 6.1°C . The temperature increase was negligible with the EPI sequence ($\Delta T_s < 0.2^\circ\text{C}$ for every subject). For the GRE and SE sequences, the mean temperature rise was $1.2 \pm 0.6^\circ\text{C}$ and $1.4 \pm 0.7^\circ\text{C}$, respectively.

Good quality GRE and SE images were obtained, i.e., the electrodes produced only minor artifacts close to the electrodes’ position, affecting only the signal from the subcutaneous fat. Figure 2 shows an example of a single-shot EPI used for the fMRI acquisition, extracted from 11 contiguous slices of a multislice EPI acquired in 960 msec. Slight intensity variations could be detected on the image acquired with the EEG system (Fig. 2b).

The EPI SNRs were also compared (without EEG: $\text{SNR} = 64 \pm 8.9, N = 8$; with EEG: $\text{SNR} = 48 \pm 7.2, N = 8$) and showed an overall decrease of $25.6\% \pm 6.0\%$ when using the EEG system inside the magnet. This

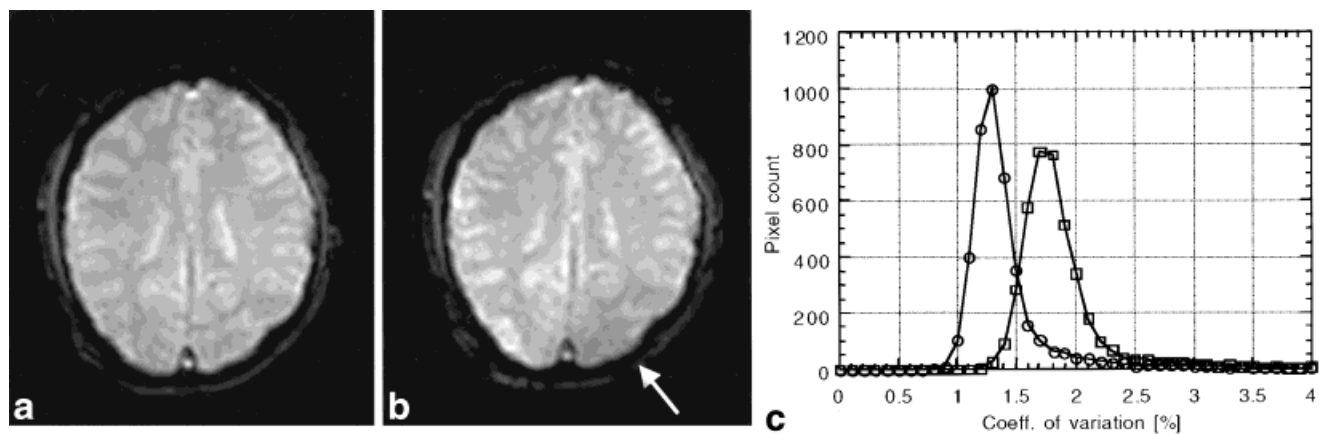


Figure 2. Single-shot EPI image without (a) and with (b) the EEG system. Only little artifacts are visible in the left occipital region due to the presence of the electrodes (arrow). c: Comparison of the coefficient of variation (SD to the mean ratio), expressed in percent, of 150 repeated measurements. The diagram represents the histogram of the coefficient of variation of the pixel time series without (circle) and with EEG (square).

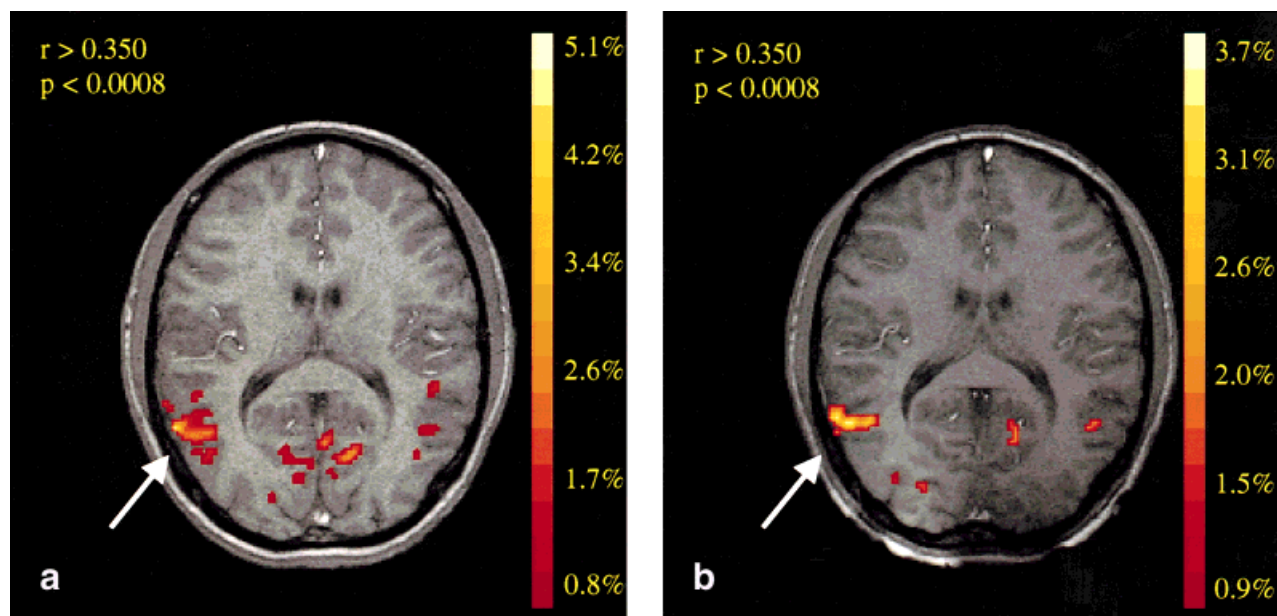


Figure 3. Visual fMRI comparison without (a) and with (b) a simultaneous 16-channel EEG recording. The image represents the area of activation determined by cross-correlation with a threshold of 0.35 (colored pixels) overlaid on a T1-weighted GRE image. The color scale represents percent signal change due to the BOLD effect. Visual motion area MT/V5 is clearly demonstrated (arrow).

decreased SNR affects the variability of the image intensity. This was assessed by computing the coefficient of variations (SD to the mean ratio) over 150 repetitions of the image, as illustrated in Fig. 2c. Nevertheless, less than 1% difference between the two measurements was observed, indicating that similar blood oxygenation level-dependent (BOLD) effects should be detected with or without the EEG system. This was conclusively demonstrated by comparing a complete fMRI experiment with and without the EEG system using motor and visual motion paradigms. Simultaneous recording of fMRI and EEG demonstrated a consistent area of activation with results obtained without EEG. The motor task activated regions in the contralateral primary motor, sensory motor, and supplementary motor cortex. The visual task demonstrated the MT/V5 area, as well as the primary visual cortex, as illustrated in Figure 3. Nevertheless, the size of the activated area was reduced in the EEG-fMRI experiment. Table 2 summarizes the fMRI findings.

The comparison of the EEG recording performed with the same setup both outside and inside the magnet

showed similar topography waveforms over the same brain regions, as shown in Figure 4. In particular, similar eye movement artifacts were found, and the posterior alpha rhythm showed similar frequency and location.

DISCUSSION

Safety

One of the concerns when recording an EEG during fMRI is the risk of skin burning due to the RF interaction with the electrodes (12). The recordings on volunteers provided very sensitive multicontact temperature probes, and no case of heat sensation at any electrode location was reported. Moreover, the temperature measurements indicate that the maximal temperature rise, on a single subject, after 3 minutes of high SAR FSE was 6.1° , which was below the allowable limit (41° for an external object in contact with the skin (12)), considering the initial skin temperature of 33° . On average, a temperature increase of less than 4° was mea-

Table 2
Data Comparison of fMRI Obtained With and Without EEG, Expressed as Mean \pm S.D.

	Task	SNR ^a	Number of pixels	CC ^b	BOLD signal [%]
No EEG	motor	58.0 \pm 5.0	123 \pm 55	0.56 \pm 0.04	4.0 \pm 0.8
With EEG	motor	43.4 \pm 6.9	55 \pm 30	0.58 \pm 0.07	5.3 \pm 0.8
No EEG	visual	72.5 \pm 7.8	45 \pm 22	0.39 \pm 0.07	3.2 \pm 0.07
With EEG	visual	52.0 \pm 1.0	28 \pm 16	0.37 \pm 0.04	3.5 \pm 0.07
% change ^c	motor	-25.7 \pm 7.3	-57 \pm 11	-3.5 \pm 8.8	-31.6 \pm 8.3
% change ^c	visual	-27.9 \pm 8.1	-41 \pm 7	4.5 \pm 6.5	-9.5 \pm 0.2

^a SNR = Signal to noise ration.

^b CC = Correlation coefficient.

^c % change represents the mean of percent change within individual subjects.

simplest way to compensate for the lower signal is to increase the voxel size, considering that a reduction of 10% in planar resolution (in two dimensions) yields more than a 20% increase in signal intensity. Another possibility is to increase the scanning time by 50% or to use a higher field strength magnet, if patient movement and safety can be insured.

In summary, the simultaneous recording of EEG and fMRI is possible and safe. Temperature measurements indicated that anatomical images with maximum allowable SAR can be performed within safety limits with the EEG system used in this study. Furthermore, the overall functionality of the EEG-fMRI examination was demonstrated and similar EEG signals, as well as similar fMRI activation, were found when compared to the acquisitions obtained independently.

ACKNOWLEDGMENTS

The authors thank Frank Henry for the acquisition of the fMRI data, Yves Ducommun-dit-Boudry for expert EEG recordings, Christoph M. Michel for providing the visual stimuli and Dominique Joliat for the maintenance of the MRI system.

REFERENCES

- Ives JR, Warach S, Schmitt F, Edelman RR, Schomer DL. Monitoring the patient's EEG during echo planar MRI. *Electroencephalogr Clin Neurophysiol* 1993;87:417-420.
- Michel CM, Grave de Peralta R, Lantz G, et al. Spatiotemporal EEG analysis and distributed source estimation in presurgical epilepsy evaluation. *J Clin Neurophysiol* 1999;16:239-266.
- Schomer DL, Bonmassar G, Lazeyras F, et al. EEG-linked functional magnetic resonance imaging in epilepsy and cognitive neurophysiology. *J Clin Neurophysiol* 2000;17:43-58.
- Warach S, Ives JR, Schlaug G, et al. EEG-triggered echo-planar functional MRI in epilepsy. *Neurology* 1996;47:89-93.
- Seeck M, Lazeyras F, Michel CM, et al. Non-invasive epileptic focus localization using EEG-triggered functional MRI and electromagnetic tomography. *Electroencephalogr Clin Neurophysiol* 1998;106:508-512.
- Krakow K, Woermann FG, Symms MR, et al. EEG-triggered functional MRI of interictal epileptiform activity in patients with partial seizures. *Brain* 1999;122:1679-1688.
- Bonmassar G, Anami K, Ives J, Belliveau JW. Visual evoked potential (VEP) measured by simultaneous 64-channel EEG and 3T fMRI. *Neuroreport* 1999;10:1893-1897.
- Felblinger J, Slotboom J, Kreis R, Jung B, Boesch C. Restoration of electrophysiological signals distorted by inductive effects of magnetic field gradients during MR sequences. *Magn Reson Med* 1999;41:715-721.
- Muri RM, Felblinger J, Rosler KM, Jung B, Hess CW, Boesch C. Recording of electrical brain activity in a magnetic resonance environment: distorting effects of the static magnetic field. *Magn Reson Med* 1998;39:18-22.
- Allen PJ, Polizzi G, Krakow K, Fish DR, Lemieux L. Identification of EEG events in the MR scanner: the problem of pulse artifact and a method for its subtraction. *Neuroimage* 1998;8:229-239.
- Krings T, Chiappa KH, Hill RA, Kwong KK, Jenkins BG. Functional MR imaging during epileptic activity. *Hum Brain Mapping* 1999;9: S573.
- Lemieux L, Allen PJ, Franconi F, Symms MR, Fish DR. Recording of EEG during fMRI experiments: patient safety. *Magn Reson Med* 1997;38:943-952.
- Woods RP, Grafton ST, Holmes CJ, Cherry SR, Mazziotta JC. Automated image registration: I. General methods and intrasubject, intramodality validation. *J Comput Assist Tomogr* 1998;22:139-152.
- Bandettini PA, Jesmanowicz A, Wong EC, Hyde JS. Processing strategies for time-course data sets in functional MRI of the human brain. *Magn Reson Med* 1993;30:161-173.
- Kanal E, Shellock FG. Burns associated with clinical MR examinations. *Radiology* 1990;175:585.
- Shellock FG, Kanal E. *Magnetic resonance. Bioeffects, safety, and patient management.* Lippincott-Raven: Philadelphia-New York; 1996.
- Baumann SB, Noll DC. A modified electrode cap for EEG recordings in MRI scanners. *Clin Neurophysiol* 1999;110:2189-2193.