

# Magnetic Resonance Spectroscopy and Imaging at 9.4T in P4 rat pup brain following cerebral hypoxia-ischemia

Y. van de Looij<sup>1,2</sup>, A. Chatagner<sup>2</sup>, N. Kunz<sup>1</sup>, P. S. Hüppi<sup>2</sup>, S. V. Sizonenko<sup>2</sup>, and R. Gruetter<sup>1,3</sup>

<sup>1</sup>Laboratory for Functional and Metabolic Imaging, Ecole Polytechnique Fédérale de Lausanne, Lausanne, Switzerland, <sup>2</sup>Division of Child Growth & Development, Department of Pediatrics, University of Geneva, Geneva, Switzerland, <sup>3</sup>Departments of Radiology, University of Geneva and University of Lausanne, Geneva and Lausanne, Switzerland

**Introduction:** In early preterm infants, periventricular leukomalacia represent the predominant form of brain injury: of those infants born weighting less than 1500 grams, 25-50% later exhibiting developmental disabilities and up to 5-15% having a more major cerebral palsy. The 3-day old rat (P3) shares some similarities in terms of cerebral development to the very preterm infant. The aim of the present study was to define the nature of diffuse injuries and potentially subsequent altered brain neurochemical development in a model of neonatal hypoxic-ischemic (HI) injury in the P3 rat pup using high-field MR imaging and spectroscopic techniques.

**Materials and Methods:** P3 Wistar pups underwent moderate (HI) injury under isoflurane anesthesia. Right carotid artery cauterization was performed then after 30 minutes rat pups were kept under hypoxia for 30 minutes at 6% O<sub>2</sub>. At 24h (P4 - n = 8) and 8 days after HI (P11 - n = 4) each pup was placed supine within an adapted holder and continuously anesthetized under a flow of 1.5-2% isoflurane in oxygen. Body temperature was maintained at 37°C using thermoregulated water circulation. All experiments were performed on an actively-shielded 9.4T/31cm magnet (Varian/Magnex) equipped with 12-cm gradient coils (400mT/m, 120μs) with a quadrature transceiver 17-mm surface RF coil. Fast Spin Echo (FSE) images with TR/TE = 6000/80 ms; FOV = 25×25 mm and matrix size = 256×256 were used to position the volume of interest (VOI) and to determinate the brain and the lesion volumes. First and second order shims were adjusted using FASTMAP [1]. The water linewidths ranged between 8 and 12 Hz for VOI of 1.5×1.5×2.5 mm<sup>3</sup>. The water signal was efficiently suppressed using VAPOR [2] and spectra acquisitions both within the cortical lesion and the contralateral cortical area were performed using STEAM (TE/TM/TR = 2.8/20/4000ms) with outer volume suppression (OVS). 35 to 70 series of FIDs (12 averages each) were acquired, individually corrected for frequency drift, summed together and corrected for residual eddy current effects using the reference water signal. Volumes (brain and lesion) were quantified using Anatomist/Brain Visa [3]. Proton spectra were analyzed with LCModel [4] using the unsuppressed water signal corrected for age-dependent changes in brain water content as an internal reference [5]. Metabolites were quantified resulting in a neurochemical profile of both the cortical lesion and the contralateral part. A Wilcoxon test was used to compare statistically metabolite concentrations between ipsilateral and contralateral side. Significant difference of the brain volumes between HI and control groups were assessed by a Mann Whitney test.

**Results and discussion:** Figure 1 shows T<sub>2</sub>-weighted FSE image of a P4, P11 rat pup brain. Arrows indicate the HI lesion. At P4 the volume of the brain in the HI group was 605 ± 63 mm<sup>3</sup> compared to control 646 ± 33 mm<sup>3</sup> and at P11, 1144 ± 208 mm<sup>3</sup> compared to control group: 1274 ± 30 mm<sup>3</sup>. Lesion volumes varied among the animals (Lesion volume at P4: 62 ± 21 mm<sup>3</sup>, at P11: 51 ± 36 mm<sup>3</sup>) due to the known variability of the model [6]. At P4 (typical spectrum of the contralateral cortex shown in figure 2), the neurochemical profile of the ipsilateral cortex indicated significant decreases for several metabolites (figure 3) including Creatine (Cr - cellular density marker), NAA (neuronal marker), Phosphorylcholine (PCho - component of cell membrane phospholipid in white matter), Taurine (Tau - implicated in osmoregulation), Glutamate (Glu - excitatory neurotransmitter), the ratio Glutamate/Glutamine (Glu/Gln - glutamatergic involvement) and an increase of Lactate (Lac - known as marker of ischemia). The modification of these metabolites reflects an acute energetic and functional slowing-down of the injured cortex that may result in subsequent abnormal development of the brain. At P11 no significant differences in metabolite concentrations between both cortices were found, ascribed to a low number of animals and possibly to intervening partial tissue repair. In conclusion, the present study is the first to investigate metabolic changes after HI in the developing brain. We show acute modifications within the injured cortex of major metabolic components after HI in P3 pups. These changes result from neuronal, glial and metabolic reaction and compromise arising from the injury. We suggest that neurochemical and volume changes may provide significant insight into the evolution of HI damage and altered brain development. Relation between metabolic changes seen with <sup>1</sup>H-MRS and severity of the injury requires further investigations.

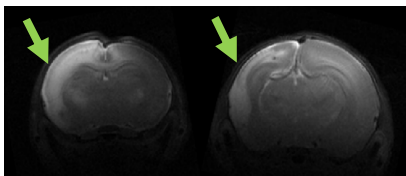


Figure 1: FSE images of a P4 and P11 rat pup brain showing abnormal development.

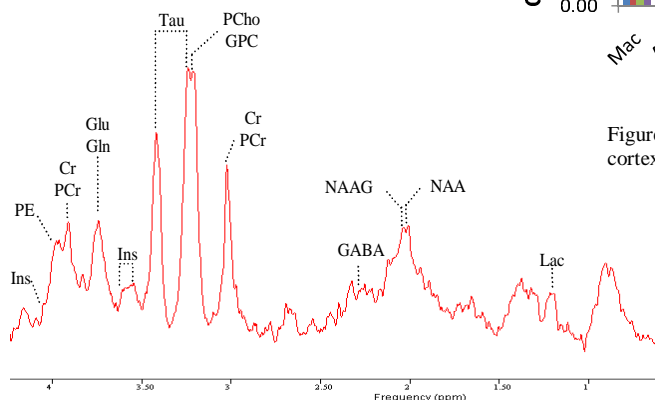


Figure 2: Typical spectrum of the contralateral cortex of a P4 rat pup

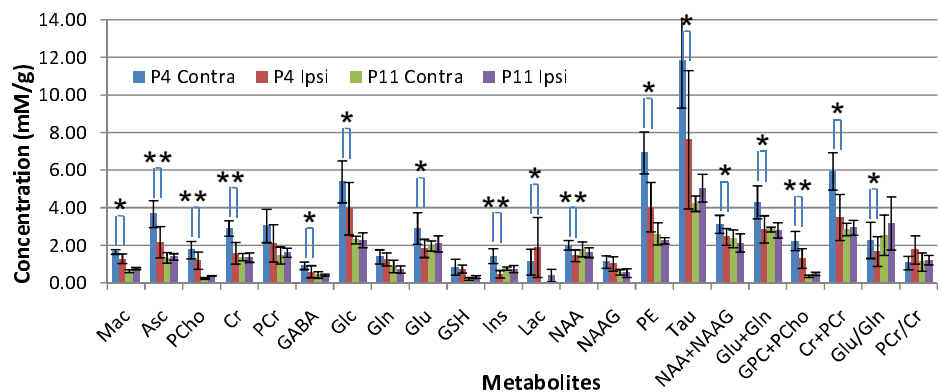


Figure 3: Evolution of metabolite concentrations from P4 to P11 in the ipsilateral and contralateral cortex. \*: p < 0.05, \*\*: p < 0.01

**References:** [1] Gruetter R et al. MRM 2000; [2] Tkác I et al. MRM 1999, [3] Cointepas Y et al. Neuroimage 2001; [4] Provencher SW et al. MRM 1993, [5] Tkác I et al. MRM 200; [6] Sizonenko S et al. Ped Res 2003.

**Acknowledgements:** Supported by the Centre d'Imagerie Biomédicale (CIBM) of the UNIL, UNIGE, HUG, CHUV, EPFL, the Leenards and Jeantet Foundation, the Fond National Suisse, Switzerland and NEOBRAIN Consortium, European Commission.